

# Right Ventricular Extension of Wilms' Tumor

M. Golmohamadi MD and H. Mehdizadeh MD

## Abstract

Wilms' tumor is the most common pediatric renal tumor, but cardiac metastases from this tumor are rare. An 8-year-old boy presented with hematuria and lower extremity pain. Computed tomography revealed a left renal mass. In addition, pre-operative echocardiography revealed a large homogenous mass in the right atrium, extending from the inferior vena cava and protruding through the tricuspid valve into the right ventricle.

The patient underwent combined radical nephrectomy and removal of the mass from the inferior vena cava and right heart chambers, followed by immunotherapy. Pathology confirmed undifferentiated Wilms' tumor in both the left kidney and the right heart chambers.

The extension of Wilms' tumor to the great vessels and the heart chambers indirectly affects the final outcome. It seems in most cases, combination surgery and chemotherapy is the choice method of treatment, and the selection of chemotherapy or surgery as the primary line of treatment depends on tumor thrombus extension and the patient's condition at the time of diagnosis (*Iranian Heart Journal 2008; 9 (4): 50 -53*).

**Key words:** cardiac tumors ■ echocardiography ■ cardiopulmonary bypass

**W**ilms' tumor (nephroblastoma) is the most common renal malignancy in childhood.

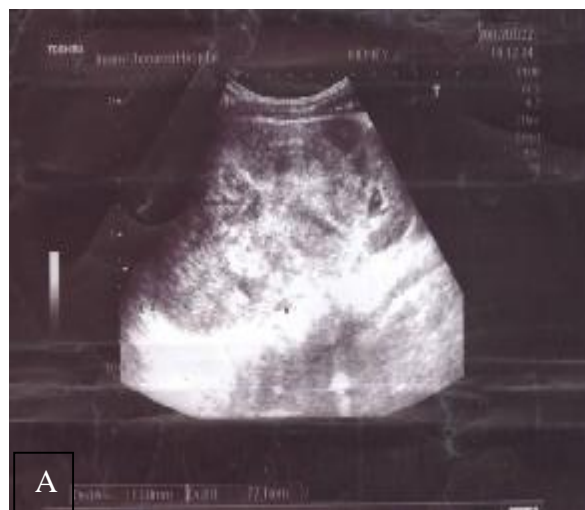The extension of the tumor into the inferior vena cava occurs in 4-10% of patients.<sup>1</sup> Much more rarely does the mass extend as far as the right heart chambers (0.7 – 4%).<sup>2</sup> We herein describe such a case with the tumor extending through the inferior vena cava into the right-sided heart chambers.

### Case report

An 8-year-old boy presented with a two-month history of lower extremity pain, followed by gross hematuria. Past medical history was negative.

On physical examination, the patient had mild dyspnea and claudication of the left leg. Laboratory data revealed only macroscopic and microscopic hematuria.

Abdominal ultrasound demonstrated a 14× 19 cm mass at the lower pole of the left kidney and numerous para-aortic lymphadenopathies (Fig. 1).



**Fig. 1.** Abdominal ultrasound views (a, b) demonstrate a 14× 19 cm mass at the lower pole of the left kidney.

Received Aug. 21, 2007; Accepted for publication Oct. 20, 2008.

Assistant Professor, Cardiac Anesthesiology Fellowship, Department of Anesthesiology, \* Assistant Professor, Cardiovascular Surgery Dept., Imam Khomeini Hospital, Ershad Blvd., Urumieh University of Medical Sciences and Health Services, Urumieh, Iran.

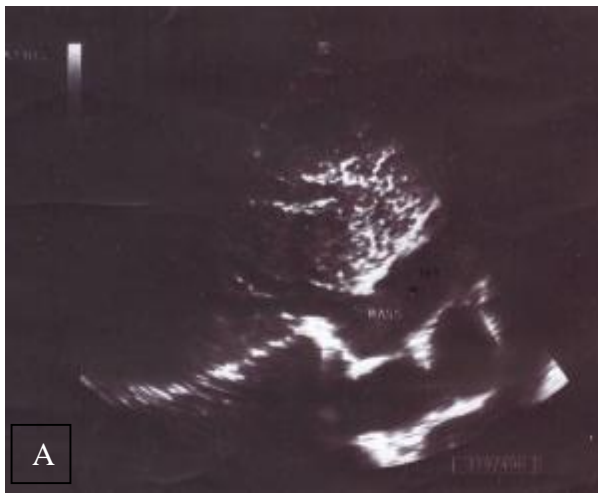
Address for Correspondence: M. Golmohammadi MD, Department of Anesthesiology, Imam Khomeini Hospital, Ershad Blvd., Urumieh University of Medical Sciences and Health Services, Urumieh, Iran.

Phone: +98-441-3447113,

Fax: +98-441-3469939,

Email: [mitragmd@yahoo.com](mailto:mitragmd@yahoo.com)

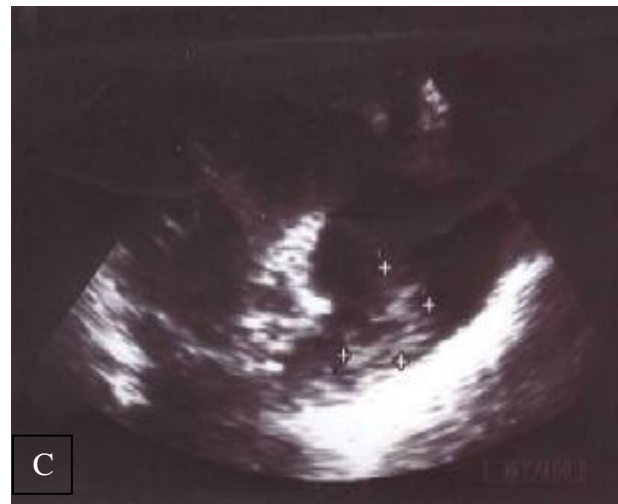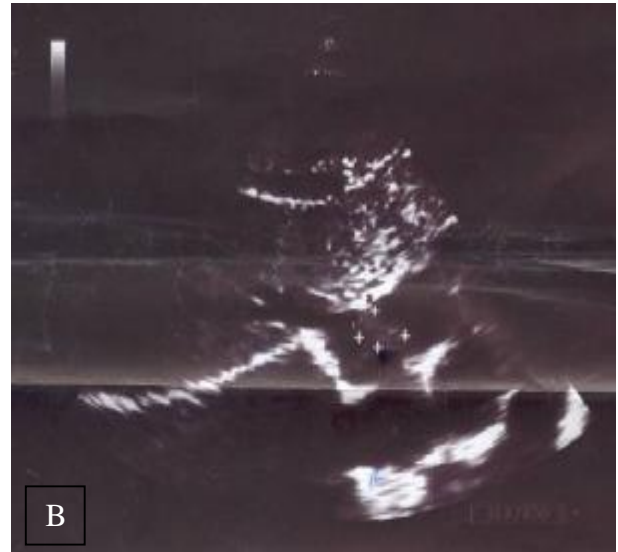
Computed tomography revealed a 10-cm mass in the left kidney and a large homogenous mass in the right atrium, extending from the inferior vena cava, and protruding into the right ventricle. Chest computed tomography showed numerous nodules in the lung, and bone scan demonstrated lytic lesions with permeation to the right iliac crest, left ischial bone, and roof of the acetabulum, indicating metastatic Wilms' tumor. Color Doppler demonstrated a normal flow through the inferior cava and tumor thrombus in the right atrium and right ventricle. Echocardiography confirmed the extension of the tumor from the inferior vena cava to the right atrium (5×7 cm mass), and right ventricle (1.7×1.9 cm mass, Fig. 2).



**Fig. 2.** Transthoracic echocardiography views show the inferior vena cava nearly filled by tumor (a), prolapsing mass into the right atrium (b) and right ventricle infiltration due to tumor thrombus (c).

The patient was diagnosed with stage IV Wilms' tumor and referred for surgery. The indication for surgery was Wilms' tumor with cardiac metastases, which could lead to the obstruction of the right ventricular outflow tract and cause congestive heart failure.

The patient underwent nephrectomy with para-aortic lymphadenectomy.



Since intravascular tumor extension with the involvement of the inferior vena cava and right heart chambers requires a precise surgical strategy, which may include extracorporeal circulation with cardiopulmonary bypass (CPB) and sometimes deep hypothermic circulatory arrest, after nephrectomy the inferior vena cava was exposed in the abdomen up to the diaphragm. Afterwards, median sternotomy and systemic heparinization were performed. Following the cannulation of the ascending aorta and right atrium, CPB was established, and cooling was continued to a core temperature of 18°C. Immediately before

circulatory arrest, the ascending aorta was cross-clamped and cardioplegia was administered for myocardial protection. Under total cardiac arrest and with a bloodless field, complete intra-caval and right atrial thrombus extraction was performed. However, a residual tumor thrombus was seen on the chordae tendinae of the anterior leaflet of the tricuspid valve and complete tumor extraction would incur the risk of tricuspid regurgitation. Therefore, tumor excision in the right ventricle was accomplished partially. After caval reconstruction and closure of the right atrium, CPB was reestablished. The aortic cross-clamp was removed, and the patient was thereafter rewarmed and weaned from CPB. The post-operative recovery was unremarkable, and chemotherapy was commenced immediately after surgery. Pathological analysis revealed a Wilms' tumor, grade IV, with undifferentiated features in both the left kidney and the right heart chambers. Follow-up after post-operative chemotherapy and radiation therapy demonstrated a gradual reduction in the right ventricle tumor mass and regression of the metastatic lesions in the bone and lung with the subsiding of the symptoms. Four months into therapy, the child is still alive with few symptoms.

### Discussion

Wilms' tumor has a strong tendency to invade the blood vessels, especially within the tumor itself and is known to invade the inferior vena cava, extending up to the right heart chambers, and leading to tricuspid valve obstruction.<sup>3</sup> Usually, the diagnosis of Wilms' tumor and tumor thrombus is made simultaneously. In 50% of the cases, clinical symptoms of such invasion may be absent.<sup>4</sup> An early diagnosis of tumor thrombus is of utmost importance so that severe complications can be prevented.<sup>5</sup> Surgical resection is the preferred approach to treat Wilms' tumor extending into the inferior vena cava and intracardiac.<sup>6</sup> Most importantly,

CPB affords the surgeon an easier and complete access, which can be life-saving, as was the case in our patient.<sup>7</sup> Furthermore, long-time survival seems to be related to the tumor histology and susceptibility to chemotherapy.<sup>3</sup> In contrast, initial chemotherapy has been used extensively by members of the International Society of Pediatric Oncology. A decrease in the size of the intravascular extension has been reported by several authors as a result of pre-operative therapy, albeit based on limited numbers of patients, and it has been further suggested that pre-operative therapy may decrease the risk of surgical complications.<sup>8,9</sup> The potential benefit of pre-operative therapy must be balanced against the disadvantages, including loss of accurate staging information.<sup>10</sup> Thompson et al. found that the resection of Wilms' tumor that extends into the vena cava or right heart results in excellent survival when combined with adjuvant therapy. A pre-operative identification of the presence of intravascular tumor thrombus and the level of vascular involvement is essential.<sup>6</sup>

### Conclusion

In conclusion, the extension of Wilms' tumor to the great vessels and heart chambers directly affects the final outcome. Although most studies have maintained that surgery after pre-operative chemotherapy has fewer complications and better results, in life-threatening situations as in our case, a primary surgical approach and post-operative chemotherapy can be successful and prolong survival. It seems in most cases, combination surgery and chemotherapy is the choice method, and the selection of chemotherapy or surgery as the first line of treatment depends on tumor thrombus extension and the patient's condition at the time of diagnosis.

### References

1. Richey M, Kelalis P, Breslow N, Offord K, Shochat S, D'Angio G. Intracaval and atrial

- involvement with nephroblastoma: review of National Wilms' Tumor Study 3. *J Urol* 1998; 140:1113-8.
2. Clayman R, Sheldon C, Gonzales R. Wilms' tumor: an approach to vena caval intrusion. *Prog Ped Surgery* 1982; 15: 285.
  3. Przybylo HJ, Stevenson GW, Backer C, Luck SR, Webb CL, Morgan E, Hall SC. Anesthetic management of children with cardiac extension of abdominal tumor. *Anesth Analg* 1994; 78: 172-175.
  4. Mesrobina H, Kelalis GJ. Wilms' tumor. 1991. AUA update series, 1991; 10: 145-48.
  5. Gibson JM, Hall-Craggs MA, Dicks-Mireaux C, Finn JP. Intracardiac extension of Wilms' tumor. Demonstration by magnetic resonance. *Br J Radiol* 1990; 63: 568-569.
  6. Thompson WR, Newman K, Seibel N, Bulas D, Kapur S, Anderson KD, Randolph J. A strategy for resection of Wilms' tumor with vena cava or atrial extension. *J Pediatr Surg* 1992; 27: 912-15.
  7. Daum R, Royh H, Zachariou M. Tumor infiltration of the vena cava in nephroblastoma. *Eur J Pediatr Surg* 1994; 4: 16-20.
  8. Berberoglu S, Akyuz C, Buyukpamukcu M. Successful treatment of intracaval and atrial extension of Wilms' tumour by chemotherapy. *Postgrad Med J* 1996; 72: 749-750.
  9. Szymik-Kontorowicz S, Urbanowicz W, Malec E, Kordon Z. Right atrial extension of Wilms' tumor. *Med Sci Monit* 2003; 9: CS13-17.
  10. Ritchey ML, Kelalis PP, Haase GM, Shochat SJ, Green DM, D'Angio G. Preoperative therapy for intracaval and atrial extension of Wilms tumor. *Cancer* 1993; 71: 4104-4110.