

# Acute Superior Vena Cava Syndrome During Drainage of Pericardial Effusion: A Case Report

Ramin Baghaee MD, Mostafa Alavi MD and Mehdi Hadadzadeh MD

## Abstract

The syndrome of superior vena cava (SVC) compression is not an uncommon entity, but acute SVC syndrome presenting in surgical patients is relatively uncommon. The case of a 64-year-old male who developed acute SVC syndrome due to mediastinal lymph node enlargement is presented here and management and special considerations are discussed (*Iranian Heart Journal 2007; 8 (3): 52-55*).

**Key words:** superior vena cava syndrome ■ mediastinal lymph node

Obstruction of the blood flow in the superior vena cava (SVC) results in symptoms and signs of SVC syndrome. SVC obstruction can be caused either by invasion or external compression of the SVC by contiguous pathologic processes involving the right lung, lymph nodes, and other mediastinal structures or by thrombosis of blood within the SVC. Occasionally, both mechanisms coexist.<sup>1</sup> We present a case of acute SVC syndrome during pericardial drainage in a patient with lymphoproliferative disorder.

## Case report

A 64-year-old man consulted the cardiac surgery service because of massive pericardial effusion. His present illness dated back to 5 years before, when he had a right submandibular mass without any symptom, which disappeared spontaneously.

From about 5 months previously, he had experienced progressive dyspnea; and 15 days prior to his referral, he had developed severe dyspnea and noticed a mass in the right side of the neck and right supraclavicular area without any symptom.

The patient denied any difficulty in swallowing or loss of range of motion in his neck. On physical examination, blood pressure was 130/70 mmHg, heart rate was 86 beats per minute, respiratory rate was 20/min, and temperature was normal. A 4 × 5 cm mass was detected in zone 2 of the right side of the neck, and cervical and supraclavicular lymphadenopathy was palpated without any tenderness.

The JVP was normal; and on chest examination, coarse rales in the lung bases were detected. Laboratory data included no electrolyte abnormalities; and WBC count was 10,400, Hb was 13.2g/dl, and platelet count was 259,000.

Received Jan 22, 2005; Accepted for publication July 4, 2007.

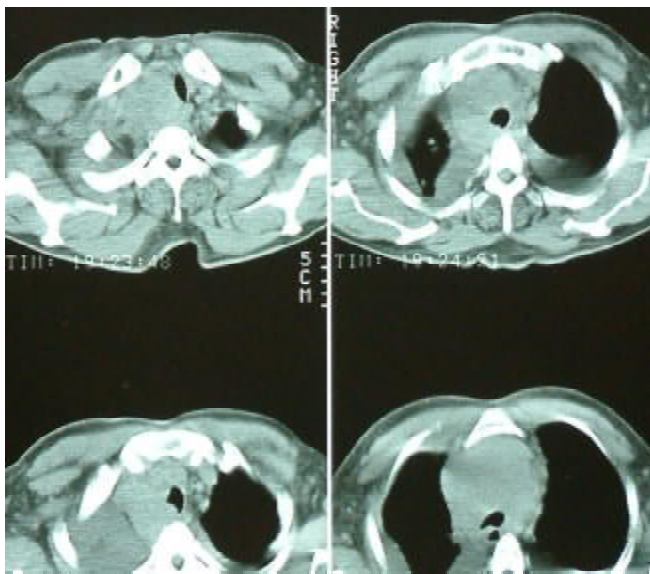
From the Department of Cardiovascular Surgery, Shaheed Rajaie Cardiovascular Medical Center, Tehran, Iran.

Address correspondence to: R. Baghaee, MD. Dept. of Cardiovascular Surgery, Shaheed Rajaie Cardiovascular Medical Center, Vali Asr Ave, Mellat Park, Tehran, Iran

Tel: 02123922589

Chest X-ray revealed widening of the mediastinal area and bilateral pleural effusions. EKG was normal. Abdominal sonography was normal.

Echocardiography revealed massive pericardial effusion. Cervical and chest CT scan revealed lymph node enlargement in the cervical and superior mediastinal areas (Fig. 1).



**Fig. 1.** CT angiography of chest.

Fine needle aspiration from the cervical mass was inconclusive, and open biopsy was recommended. However, upon waiting for open biopsy, the patient suddenly developed severe dyspnea and consulted with our service for emergency evacuation of the pericardial effusion. After the usual preoperative preparations, he was taken to the operating room for subxyphoid drainage through a pericardial window.

Under light intravenous sedation and local anesthesia, the operation was performed and approximately 1000mL fluid was drained from the pericardial sac. During the procedure, the patient suffered progressive

respiratory distress accompanied by wheezing and facial plethora. Engorgement of the head and neck soft tissues (puffiness) and superficial veins as well as signs of central cyanosis were noticed, together with elevation of central venous pressure. In order to relieve the symptoms of this acute SVC syndrome, the patient was positioned in the semi-upright position with an increase in nasal oxygen supply. Intravenous corticosteroids and diuretics were infused through an I.V. line inserted in the lower limb. After about 15 minutes of supportive measures, he recovered without any symptoms of respiratory distress or cyanosis. The operation was completed and he was transferred to the intensive care unit. The postoperative course was unremarkable, and he was discharged about 10 days later.

### Discussion

Obstruction of the blood flow in the superior vena cava results in symptoms and signs of superior vena cava (SVC) syndrome. Obstruction can either be caused by a blockage within the vessel itself, such as thrombosis, or from external compression of the SVC by pathologic processes involving the right lung, lymph nodes, and other mediastinal structures. When an obstruction of the flow through the SVC develops, venous collaterals begin to form. The rate of the obstruction will determine the body's ability to adapt in forming these collaterals. In conditions in which the rate of obstruction occurs more rapidly such as malignant disease, patients may develop symptoms of SVC syndrome in weeks to months as compared to fibrosing mediastinitis due to infection, which may take years to develop symptoms.<sup>1-5</sup> The most commonly reported symptom is dyspnea. Patients also frequently complain of facial swelling or "full-headedness", a symptom that may be exacerbated by bending over or lying down, coughs, arm edema, and cyanosis. The most common finding on physical examination is

venous distention in the neck and chest wall, and facial edema.<sup>1</sup>

Lung cancer is the most common malignant cause of SVC syndrome, followed by lymphoma; together they represent 94% of cases of SVC syndrome. Other malignancies that metastasize to the mediastinum can also be responsible. In both cases, approximately 2-4% of patients with either lung cancer or lymphoma will develop SVC syndrome through external compression of the SVC.<sup>2</sup> Non-malignant disorders account for the remaining 6-15% of SVC syndrome, of which fibrosing mediastinitis most commonly due to *Histoplasmosis* infection comprises 50%.<sup>1,2,5</sup> Other non-malignant causes include nocardiosis, sclerosing cholangitis, sarcoidosis, and post-radiation fibrosis. Thrombosis accounts for a significant percentage of the non-malignant causes of SVC syndrome and is actually the fast growing population of new cases.<sup>3</sup> This is mainly due to the increasing demand for pacemaker insertions, in which indwelling catheters or lines cause turbulent flow leading to thrombus formation. Finally, patients who have hypercoagulable conditions such as Protein C or S deficiency, Factor V Leiden deficiency, and many others are at higher risk for thrombus formation.<sup>3</sup> Diagnosis most commonly can be made by chest x-ray due to the fact that the majority of cases are caused by external compression from a solid tumor or lymph node. Other radiographic studies used are CT scan and venography. Venography is considered the gold standard for the diagnosis of SVC syndrome. It is helpful in showing the location and the degree of blockage; although it has limitations in helping with identifying the primary cause of the obstruction unless it is purely an intravascular process. MRI can be used for patients with contrast allergies.<sup>4,5</sup>

Treatment is directed toward the underlying disease causing SVC syndrome. Radiation and/or chemotherapy are effective in patients with cancer. Malignancies that have high rates of response to chemotherapy will usually show rapid regression of SVC syndrome.

Thrombolytics play a role in patients who are eligible and are used for patients with either refractory disease or who need immediate symptomatic improvement.<sup>2,3</sup>

### Special Considerations

The preoperative anesthetic evaluation of a patient with SVC syndrome should include a careful assessment of the airway. The same degree of edema that is present externally in the face and neck can be expected to be present in the mouth, oropharynx, and hypopharynx.

In addition, the airway may be compromised by external compression, fibrosis limiting normal movement, or recurrent laryngeal nerve involvement.

The patient should be transported to the operating room in the head-up position to minimize airway edema. Central venous or pulmonary artery catheters, if needed, are inserted via the femoral vein before the induction of anesthesia; and at least one other large-bore IV catheter should be inserted in the leg before surgery.

Premedication is best limited to an anti-sialogue to reduce airway secretions. If it is necessary for the patient to maintain the sitting position, to achieve adequate ventilation before induction, intubation with the patient awake may be facilitated by using a fiber optic laryngoscope or bronchoscope. Postoperatively, especially when the SVC obstruction has not been relieved, acute severe respiratory failure requiring intubation and mechanical ventilation may occur. The mechanism of the acute respiratory failure is obscure, but the most likely areas that are unique to the SVC syndrome are acute laryngospasm and/or acute bronchospasm (both due to continued and perhaps increased obstruction of the SVC), impaired respiratory muscle function (patient with malignant disease may have an abnormal response to muscle relaxants), and increased airway obstruction by the tumor (due to tumor swelling). Consequently, these patients must be closely monitored in the

first few postoperative hours.<sup>6</sup> Our patient most probably had “subclinical” SVC syndrome before the induction of anesthesia. Nevertheless, after induction, most probably due to lymph node edema of the mediastinal area, he developed acute symptoms. Furthermore, after the rapid drainage of pericardial effusion, external compression of the SVC by superior mediastinal lymph nodes became more prominent. With proper management, the patient recovered.

### References

1. Abner A. Approach to the patient who presents with superior vena cava obstruction. *Chest* 1993; 103: 394S.
2. Roberts JR, Bueno R, Sugarbaker DJ. Multimodality treatment of malignant superior vena caval syndrome. *Chest* 1999; 116: 835.
3. Greenburg S, Klonski R, Daniels J. Treatment of superior vena cava thrombosis with recombinant type tissue plasminogen activator. *Chest* 1991; 99: 1298.
4. Mahajan V, Strimlan V, Ordstrand HS, Loop FD. Benign superior vena cava syndrome. *Chest* 1975; 68: 32-5.
5. Swchowengert CG, Suyemoto R, Main BF. Granulomatous and fibrous mediastinitis. *J Thorac Cardiovasc Surg* 1969: 365.
6. Miller R, Fleisher L, Johns R. Textbook of Anesthesia, 2001, pp. 1921-1923.