

Value of Posterior Leads (V7-V9) in Diagnosis of Posterior Wall ST Segment Elevation Myocardial Infarction

Reza Miri MD, Arash Rashidi MD* and Hamid Akbarshahi, MD

Abstract

Background- The standard 12-lead electrocardiogram (ECG) has relatively low sensitivity for the diagnosis of posterior wall acute myocardial infarction (AMI). The prevalence of posterior wall myocardial infarction (MI) has been studied in a few studies. We evaluated ST-segment elevation (STE) prevalence in posterior leads in patients with acute coronary syndrome (ACS) in order to determine the prevalence of posterior wall MI and the value of posterior ECG leads in diagnosing it.

Methods- Patients who were admitted with ACS during a 12-month period to our department were included in the study. Posterior electrocardiogram (V7-V9) was obtained in addition to the standard 12-lead electrocardiogram in the emergency room (ER) and also in the cardiac care unit (CCU). All ECGs were reviewed by a cardiologist for the presence of STE of at least 0.5 mm in two or more leads of V7-V9.

Results- In total, 230 patients were diagnosed with AMI based on the World Health Organization criteria, out of 506 patients who were admitted with ACS. In addition, 146 patients (63.47%) had criteria of STE MI in 12-lead standard ECG and 84 patients (36.52%) had non-STE myocardial infarction on standard ECG. Five patients (6%, 95% CI; 2-13.3%) had STE in posterior leads without STE in the standard 12-lead ECG and initially were diagnosed as non-STE myocardial infarction. Overall, 31 patients (13.5%, 95% CI; 9.3-18.6%) had posterior STE myocardial infarction in 15-lead ECG, of which 18 cases (58.1%, 95% CI; 39.1-75.5%) were accompanied with inferior MI, 3 cases (9.7%, 95% CI; 2-25.8%) with anterior MI and 5 cases (16.1%, 95% CI; 5.5-33.7%) with anteroseptal MI in the standard ECG.

Conclusion- The diagnosis of isolated posterior MI or posterior MI in the presence of other myocardial wall infarction is a challenging diagnosis. These patients may have normal standard ECGs. Obtaining posterior leads will lead to the diagnosis of posterior wall STE MI in a significant number of patients (*Iranian Heart Journal 2007; 8 (4): 24-28*).

Key words: myocardial infarction ■ electrocardiography ■ posterior leads

Serial ECGs are still used for the diagnosis of acute myocardial infarction (AMI). However, the standard 12-lead ECG has relatively low sensitivity for the diagnosis of posterior wall AMI.

This is especially important for decision-making about reperfusion therapy. The most important problem of the standard ECG is that no leads are directly located adjacent to the posterior heart walls.

Received July 27, 2006; Accepted for publication November 11, 2007.

From the Department of Cardiology, Imam Hosein (AS) Hospital, Shaheed Beheshti University of Medical Sciences, Tehran, Iran and *Fairview Hospital, Cleveland Clinic Health System, Cleveland, Ohio, USA.

Correspondence to: R. Miri, MD, Dept. of Cardiology, Imam Hosein (AS) Hospital, Shaheed Beheshti University of Medical Sciences, Tehran, Iran

V1, V2 and V3 are precordial leads which are in front of the anterior heart wall, and in the case of posterior wall MI, they can show reciprocal changes.^{1,2} Diagnostic criteria for posterior wall MI in anterior leads are: taller R wave than S wave ($R/S > 1$) in leads V1-V2 and/or pathologic Q wave in V6 and/or V7 and sometimes in leads I, aVL and V6. Tall R wave in V1 can also be seen in right ventricular hypertrophy (RVH), right bundle branch block and pre-excitation syndrome.³ These changes lack high specificity and sensitivity and could be seen in anterior MI too, and in this case could lose the benefit of thrombolytic therapy.⁴ In the present study, we report electrocardiographic findings and prevalence of STE in posterior leads in 506 patients who were admitted with the diagnosis of acute coronary syndrome in our center.

Methods

The study population consisted of 506 patients who were admitted to the CCU ward of Imam Hosein (A.S.) Hospital. Immediately after admission to ER and also after admission to CCU, posterior ECG (leads V7-V9) was obtained in addition to the standard 12-lead electrocardiogram. In each patient, 4 series of 15-lead ECGs were obtained. Posterior leads were obtained by placing ECG leads along the fifth intercostal space at the left posterior axially line (V7), midscapular line (V8) and paravertebral line (V9).

Resident physicians completed prospective data collection sheets at the time of their initial patient evaluations. Data collected included age, gender, presenting symptom, history of MI or angina and presence of pain during ECG.

All ECGs were reviewed by a cardiologist for the presence of STE of at least 0.5 mm in two or more leads of V7-V9.

As suggested by previous studies,^{5,6} an ST-segment elevation of 0.5mm was considered significant in the posterior chest leads, because of the greater distance separating the posterior chest wall from the heart. AMI was

diagnosed according to the World Health Organization criteria.

Data Analysis

Data was stored in a specifically designed questionnaire in Epiinfo 2002 Statistical Software, and analysis was done using the same software. Results are presented as mean value \pm SD for continuous variables and as frequency with 95% CI (confidence intervals) for discrete variables.

Results

During a 12-month period from August 2001 to August 2002, 506 patients consisting of 217 females (42.9%) and 289 males (57.1%) were admitted with the diagnosis of acute coronary syndrome (ACS). The average age of males was 58.2 ± 12.62 years, and 63.46 ± 11.34 in females. Overall, 230 patients were diagnosed with AMI, 64 of whom were females and 166 were males. Among 230 patients with AMI, 146 patients (63.47%) had the criteria of STE MI according to 12-lead standard ECG and 84 patients (36.52%) had non-STE MI. When the data of posterior leads were included, 151 patients (65.65%) were classified as STE myocardial infarction and 79 patients (34.34%) as non-STE myocardial infarction. This means that 5 patients had STE in posterior leads, without STE in standard 12-lead ECG. Those patients, without considering posterior lead data, would have been classified as non-STE myocardial infarction and not STE myocardial infarction. On the other hand, 6% (95% CI; 2-13.3%) of patients with diagnosis of non-STE in standard 12-lead ECG were diagnosed as STE myocardial infarction in 15-lead ECG. Overall, 31 patients (13.5%, 95% CI; 9.3-18.6%) had posterior STE myocardial infarction in 15-lead ECG, 18 cases of which (58.1%, 95% CI; 39.1%-75.5%) were accompanied with inferior MI, 3 cases (9.7%, 95% CI; 2%-25.8%) with anterior MI and 5 cases (16.1%, 95% CI; 5.5-33.7%) with anteroseptal MI in standard ECG tracings. On

the other hand, 30.5% (95% CI; 5.19-43.9%) of cases with inferior MI had posterior MI as well, and it was 10.3% (95% CI; 2.2-27.4%) and 8.6% (95% CI; 2.9-19.0%) in anterior and anteroseptal MI's, respectively (Table I).

Table I. Results with and without considering posterior leads.

WITHOUT POST LEADS	NON- ST ELEVATED MI	NO.	PERCENT
			84
	ST ELEVATED MI	146	63.48%
WITH POST LEADS	NON- ST ELEVATED MI	79	34.34%
	ST ELEVATED MI	151	65.66%

Discussion

Classically, ECG diagnosis of posterior wall infarction is based on the appearance of a prominent R wave in leads V1 and V2, but these R waves might appear hours after the onset of symptoms. Previous investigators⁷⁻¹² have suggested that precordial ST segment depression during the acute stage of inferior MI might be related to posterior wall involvement. However, such precordial ST segment depression might also reflect anterior wall ischemia or non-STE myocardial infarction.¹³⁻¹⁸ Consequently, this ECG sign has low to moderate sensitivity and specificity for posterior wall infarction.^{7,8} It has been shown that in 20% of patients with MI and without ST segment elevation (STE) in standard leads, ST segment was elevated in posterior leads (V7-V9). In 2-20% of patients who had enzymatic criteria of AMI, STE could be seen only in posterior leads.^{19,20} STE in V7-V9 will help to differentiate posterior

wall MI from anterior wall ischemia and it would affect the decision about thrombolytic therapy.^{1,2,21} In these patients, diagnosis of STE in posterior leads would lead to thrombolytic therapy or PTCA; and in case of anterior ischemia, they would be candidates for anti-thrombotic therapies.²² Isolated posterior MI is an even more challenging diagnosis. These patients may have normal standard ECGs or may masquerade as non-STE myocardial infarction.²³ The addition of posterior leads may prove to be a valuable tool in the diagnosis of such cases. This has been shown to increase the sensitivity of ECGs to detect posterior AMIs.

In a study by Oraili and co-workers on 210 patients with MI, STE in two or three leads was observed in 9% of cases. They showed that in 10.9% of patients with non-STE myocardial infarction in standard leads, STE existed in posterior leads.²⁵ Melendez and co-workers showed that in 20% of patients with AMI, there was STE in 2 or 3 posterior leads. They showed that in 7% of them, STE was only observed in posterior leads and not standard leads.¹⁹ In a study by Agarwal and co-workers in 58 patients with non-STE myocardial infarction based on the standard ECG, STE was observed in posterior leads in 18 patients (Fig. 1).²⁶

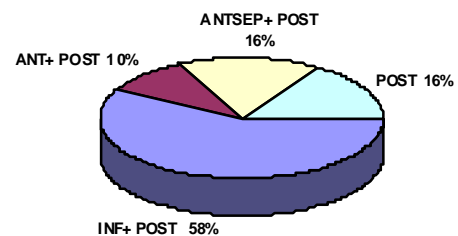


Fig. 1. Association of posterior MI with infarction of other regions of myocardium.

The usefulness and accuracy of posterior leads in detecting STE has also been shown in other studies.^{27,28}

In this study, prevalence of STE in posterior leads in patients who were diagnosed as non-STE myocardial infarction was 6%, and obtaining posterior leads changed the management of those patients. This study also showed that 30.5% of patients with inferior MI had simultaneous posterior MI as well. Matetetzky and co-workers showed that patients with an inferior MI with STE in posterior leads might benefit more from revascularization therapy than those with inferior MI without STE in posterior leads.⁷

In conclusion, obtaining posterior lead ECGs would change the diagnosis of non-STE MI to STE MI in at least 6% of patients who otherwise would not benefit from reperfusion therapy because of misdiagnosis.

Undiagnosed posterior wall STE myocardial infarction in standard leads is not uncommon and it is important especially in inferior MI and non-STE myocardial infarction patients in whom undiagnosed STE would change their outcome.

Acknowledgments

This research project has been supported by Shahid Beheshti University of Medical Sciences. We express our appreciation to the CCU and ER nurses of Imam Hosein (A.S.) Hospital for their enthusiastic participation in this study. The authors also wish to thank Dr. Kavitha Srinivasan who revised the English edition of the manuscript.

References

- Huey BL, Beller GA, Kaiser DL, Gibson RS. A comprehensive analysis of myocardial infarction due to left circumflex artery occlusion: comparison with infarction due to right coronary artery and left anterior descending artery occlusion. *J Am Coll Cardiol* 1988 Nov; 12 (5): 1156-66.
- Bush HS, Ferguson JJ IIIrd, Angelini P, Willerson JT. Twelve-lead electrocardiographic evaluation of ischemia during percutaneous transluminal coronary angioplasty and its correlation with acute reocclusion. *Am Heart J* 1991 Jun;121 (6 Pt 1): 1591-9.
- Dunn MI, Lipman BS. Myocardial infarction, injury and ischemia. In: Lipman-Massie, *Clinical Electrocardiography*. 8th edition, Year Book Medical Publishers, 1989; pp. 160-209.
- the TIMI III B investigators: Effects of tissue plasminogen activator and a comparison of early invasive and conservative strategies in unstable angina and non-Q-wave myocardial infarction. Results of TIMI IIIB Trial. *Circulation* 89: 1545, 1994.
- Elek R, Herman LM, Griffith GC. A study of unipolar left back leads and their application to posterior myocardial infarction. *Circulation* 1953; 7 suppl VII: VII-656-8.
- Lew AS, Maddahi J, Shah PK, Weiss AT, Peter T, Berman DS, Ganz W. Factors that determine the direction and magnitude of precordial ST-segment deviations during inferior wall acute myocardial infarction. *Am J Cardiol* 1985 Apr 1; 55(8): 883-8.
- Goldberg HL, Borer JS, Jacobstein JG, Kluger J, Scheidt SS, Alonso DR. Anterior ST-segment depression in acute inferior myocardial infarction: indicator of posterolateral infarction. *Am J Cardiol* 1981 Dec; 48(6): 1009-15.
- Croft CH, Woodward W, Nicod P, Corbett JR, Lewis SE, Willerson JT, Rude RE. Clinical implications of anterior ST-segment depression in patients with acute inferior myocardial infarction. *Am J Cardiol* 1982; 50(3): 428-36.
- Gibson RS, Crampton RS, Watson DD, Taylor GJ, Carabello BA, Holt ND, Beller GA. Precordial ST-segment depression during acute inferior myocardial infarction: clinical, scintigraphic and angiographic correlations. *Circulation* 1982 Oct; 66 (4): 732-41.
- Ong L, Valdellon B, Coromilas J, Brody R, Reiser P, Morrison J. Precordial ST-segment depression in inferior myocardial infarction. Evaluation by quantitative thallium-201 scintigraphy and technetium-99m ventriculography. *Am J Cardiol* 1983; Mar 51(5): 734-9.
- Hlatky MA, Califf RM, Lee KL, Pryor DB, Wagner GS, Rosati RA. Prognostic significance of precordial ST-segment depression during

- inferior acute myocardial infarction. *Am J Cardiol* 1985 Feb; 55(4): 325-9.
12. Lew AS, Weiss AT, Shah PK, Maddahi J, Peter T, Ganz W, Swan HJ, Berman DS. Precordial ST segment depression during acute inferior myocardial infarction: early thallium-201 scintigraphic evidence of adjacent posterolateral or inferoseptal involvement. *J Am Coll Cardiol* 1985 Feb; 5 (2Pt1): 203-9.
 13. Shah PK, Pichler M, Berman DS, Maddahi J, Peter T, Singh BN, Swan HJ. Noninvasive identification of a high risk subset of patients with acute inferior myocardial infarction. *Am J Cardiol* 1980 Dec 1;46 (6): 915-21.
 14. Salcedo JR, Baird MG, Chambers RJ, Beanlands DS. Significance of reciprocal ST-segment depression in anterior precordial leads in acute inferior myocardial infarction: concomitant left anterior descending coronary artery disease? *Am J Cardiol* 1981 Dec; 48 (6): 1003-8.
 15. Haraphongse M, Jugdutt BI, Rossall RE. Significance of precordial ST-segment depression in acute transmural inferior infarction: coronary angiographic findings. *Cathet Cardiovasc Diag* 1983; 9(2): 143-51.
 16. Billadello JJ, Smith JL, Ludbrook PA, Tiefenbrunn AJ, Jaffe AS, Sobel BE, Geltman EM. Implications of "reciprocal" ST segment depression associated with acute myocardial infarction identified by positron tomography. *J Am Coll Cardiol* 1983 Oct; 2 (4): 616-24.
 17. Roubin GS, Shen WF, Nicholson M, Dunn RF, Kelly DT, Harris PJ. Anterolateral ST-segment depression in acute inferior myocardial infarction: angiographic and clinical implications. *Am Heart J* 1984 Jun; 107 (6): 1177-82.
 18. Matetzky S, Novikov M, Gruberg L, Freimark D, Feinberg M, Elian D, Novikov I, Di Segni E, Agranat O, Har-Zahav Y, Rabinowitz B, Kaplinsky E, Hod H. The significance of persistent ST elevation versus early resolution of ST segment elevation after primary PTCA. *J Am Coll Cardiol* 1999 Dec; 34 (7): 1932-8.
 19. Melendez LJ, Jones DT, Salcedo JR. Usefulness of three additional electrocardiographic chest leads (V7, V8, and V9) in the diagnosis of acute myocardial infarction. *Can Med Assoc J* 1978 Oct 7; 119 (7): 745-8.
 20. Zalenski RJ, Cooke D, Rydman R, Sloan EP, Murphy DG. Assessing the diagnostic value of an ECG containing leads V4R, V8, and V9: the 15-lead ECG. *Ann Emerg Med* 1993 May; 22 (5): 786-93.
 21. Berry C, Zalewski A, Kovach R, Savage M, Goldberg S. Surface electrocardiogram in the detection of transmural myocardial ischemia during coronary artery occlusion. *Am J Cardiol* 1989 Jan 1; 63 (1): 21-6.
 22. Matetzky S, Freimark D, Feinberg MS, Novikov I, Rath S, Rabinowitz B, Kaplinsky E, Hod H. Acute myocardial infarction with isolated ST-segment elevation in posterior chest leads V7-9: "hidden" ST-segment elevations revealing acute posterior infarction. *J Am Coll Cardiol* 1999 Sep; 34 (3): 748-53.
 23. Braunwald E: *Heart Disease, A Text book of Cardiovascular Medicine* 5th edition. Saunders, Philadelphia 1997 Topas, O., Rechavia, E., et al.
 24. Zalenski RJ, Rydman RJ, Sloan EP, Hahn KH, Cooke D, Fagan J, Fligner DJ, Hessions W, Justis D, Kampe LM, Shah S, Tucker J, Zwicke D. Value of posterior and right ventricular leads in comparison to the standard 12-lead electrocardiogram in evaluation of ST-segment elevation in suspected acute myocardial infarction. *Am J Cardiol* 1997 Jun 15; 79 (12): 1579-85.
 25. Oraili S, Maleki M, Tavakolian AA, Eftekharzadeh M, Kamangar F, Mirhaji P. Prevalence and outcome of ST-segment elevation in posterior electrocardiographic leads during acute myocardial infarction. *J Electrocardiol* 1999 Jul; 32 (3): 275-8.
 26. Agarwal JB, Khaw K, Aurignac F, LoCurto A. Importance of posterior chest leads in patients with suspected myocardial infarction, but nondiagnostic, routine 12-lead electrocardiogram. *Am J Cardiol* 1999 Feb 1; 83 (3): 323-6.
 27. Casas RE, Marriott HJ, Glancy DL. Value of leads V7-V9 in diagnosing posterior wall acute myocardial infarction and other causes of tall R waves in V1-V2. *Am J Cardiol* 1997 Aug 15; 80 (4): 508-9.
 28. Rich MW, Imburgia M, King TR, Fischer KC, Kovach KL. Electrocardiographic diagnosis of remote posterior wall myocardial infarction using unipolar posterior lead V9. *Chest* 1989 Sep; 96 (3): 489-93.