

# Aortic Aneurysm in Takayasu's Syndrome

Ali Sadeghpour Tabae MD\*, Shahryar Mali MD\*\*, Jalal Vahedian MD\*\*\*  
and Soheila Arefi MD\*\*\*\*

## Abstract

Ascending aortic aneurysm is a relatively rare complication of Takayasu's arteritis. We report a 54 year old lady, a known case of Takayasu's syndrome, who was operated for the second time because of aneurysmal change in the ascending aorta (*Iranian Heart Journal 2008; 9 (2):55-58*).

**Key words:** aortic aneurysm ■ Takayasu's syndrome ■ aortitis ■ pulselessness

**T**akayasu's arteritis is a primary arteritis of unknown etiology that commonly affects the aorta and its major branches, as well as the pulmonary artery.

The disease involves the vessel walls and results in luminal abnormalities including stenosis, occlusion, and aneurysm formation.<sup>1-5</sup>

The long-term prognosis for patients with Takayasu's arteritis is relatively good.<sup>6,7</sup>

However, its aneurysmal complications can progress to a fatal outcome such as rupture, which has the most frequent fatal course and heart failure due to aortic valve regurgitation.

In this report we present a case of Takayasu's syndrome complicated with aneurysm of the ascending aorta.

### Case report

A 54 year-old lady with history of previous aortic valve replacement (AVR) 12 years before, was referred to our center due to dyspnea and was admitted with the impression of aortic valve (AV) malfunction.

About 12 years previously, she was admitted with a 5-year history of dyspnea and 5 months' history of fever and skin lesions and with the impression of subacute bacterial endocarditis, she was operated (AVR).

The surgeon found aortic valve thickening and inflammation, accompanied by aortitis. The aortic valve was replaced with a prosthetic heart valve (25mm). Pathologic evaluation suggested luetic aortitis (syphilitic), but the diagnosis was not confirmed with serologic tests. The postoperative course was uneventful and the patient was discharged, albeit with a high sedimentation rate (ESR=80). About one year later, the patient presented with a chief complaint of syncopal attack. She had complaints of weakness and claudication of the left arm, orthostatic hypotension and decreased vision (she had decreased vision in the lower field of the left eye and then complete loss of vision in the left eye for about 5 minutes).

Physical examination revealed hypertension and unequal upper extremity pulses.

In selective aortic angiography, fusiform dilatation at the bifurcation of the right carotid artery and right subclavian artery and significant stenosis of the origin of the innominate artery was seen, with the impression of Takayasu's arteritis (Shimizu-Sano type). The patient was successfully treated with medical therapy.

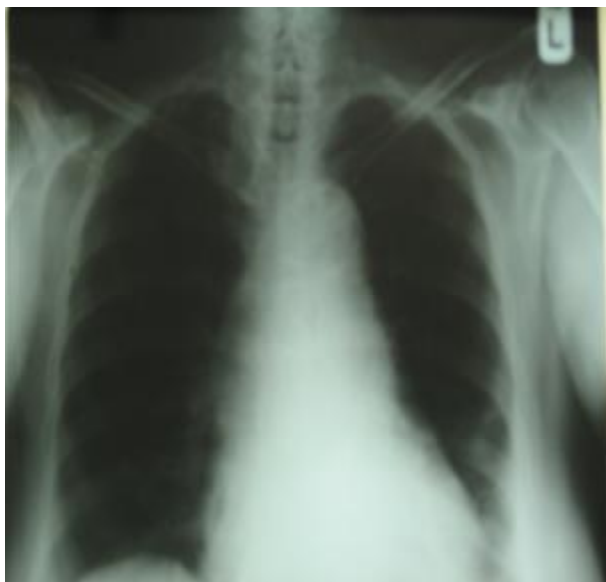
Received Oct . 2 2007; Accepted for publication May 2, 2008.

\*Associate Professor of Cardiovascular Surgery; \*\* Resident of Cardiovascular Surgery, Shaheed Rajaei Cardiovascular Medical Center, Mellat Park, Vali Asr Ave. Tehran, Iran, \*\*\* Associate Professor of Surgery, Firouzgar Hospital and Research Center, Iran University of Medical Sciences and Health Services, Vali-Asr Street, Valadi Avenue, Tehran, Iran, \*\*\*\* Assistant Professor of Reproductive Endocrinology Department, Avicenna Research Center, Shaheed Beheshti University of Medical Sciences, Evin, Tehran, Iran.

Correspondence to: Ali Sadeghpour Tabae MD; Dept. of Cardiovascular Surgery; Shaheed Rajaei Cardiovascular Medical Center, Mellat Park, Vali Asr Ave. Tehran, Iran, Tel: 02123922589

In her recent admission to our unit, physical examination revealed hypertension, a bruit at the left carotid artery, a systolic and diastolic murmur at the aortic valve region and unequal pulses. The left carotid and radial pulses were markedly reduced.

Chest x-ray showed moderate to severe calcification of the aortic arch and descending aorta, and fluoroscopy revealed abnormal motion of the prosthetic valve leaflets (Fig. 1, 2). Transesophageal echocardiography showed an ejection fraction of 45-50%, malfunction of the aortic valve prosthesis, clot formation on the ventricular side of the aortic valve, large aneurysm of the ascending aorta, moderate transvalvular leak and severe pulmonary artery hypertension.



**Fig. 1.** Chest x-ray, PA view showing moderate calcification of the aortic arch and descending aorta

With a diagnosis of ascending aortic aneurysm and prosthetic valve malfunction, the patient was operated. At surgery, a very large ascending aortic aneurysm (8 cm in diameter) was found, with severely calcified walls which extended to the transverse arch and descending aorta.

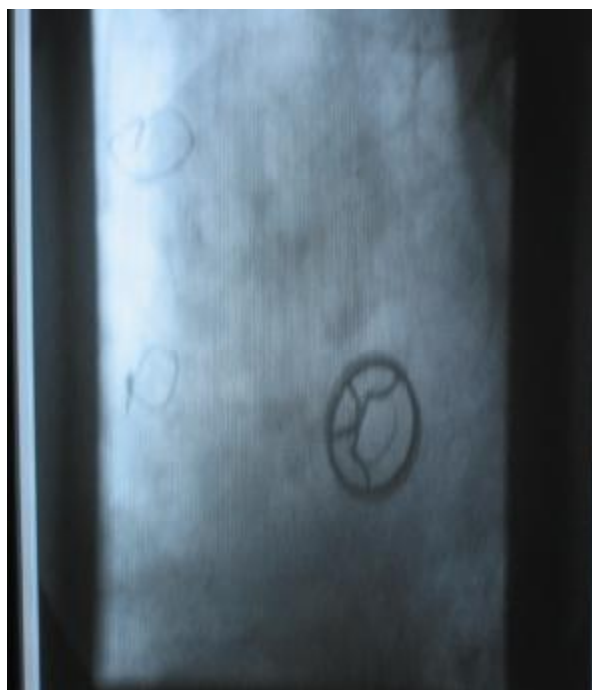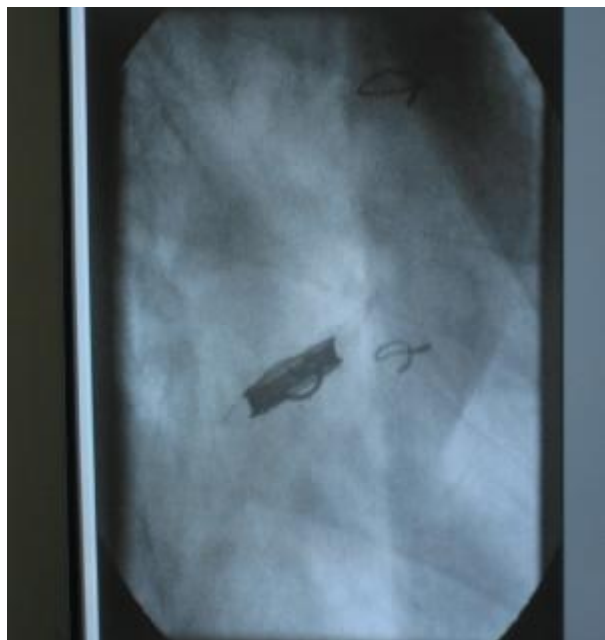After explanting the prosthetic aortic valve, a classic Bentall operation was done (composite graft no. 28 with a Carbomedics valve no. 25). Postoperative course was unremarkable and the patient was discharged with satisfactory general condition.

## Discussion

Takayasu's arteritis is a primary arteritis of unknown etiology involving the vessel walls that results in abnormalities including stenosis, occlusion and aneurysmal formation.<sup>1-5</sup> Although stenotic lesions are identified frequently, aneurysm formation is the most fatal complication in Takayasu's arteritis.<sup>6,7</sup> To our knowledge, only a few reports have focused on aortic aneurysm in patients with Takayasu's arteritis.<sup>8</sup> For the diagnosis of Takayasu's arteritis, conventional angiography has been regarded as necessary. However, a recent report has showed that CT scan clearly delineates aortic mural changes that are difficult to detect on conventional angiography, including wall thickening, calcification and mural thrombus. In this case, selective angiography of the aorta was performed,<sup>3</sup> and revealed stenosis and dilatation of the aortic branches. Because CT scan was not performed, we had no information about the aortic wall at first evaluation and the extent of the aneurysm formation in the preoperative evaluation. Several reports have described aneurysm formation as being rarely associated with Takayasu's arteritis.

The incidence of aneurysm formation in patients with Takayasu's arteritis varies from 0% to 87.5%.<sup>8,13,14</sup>

Pathologic studies of Takayasu's arteritis have revealed marked thinning of media, marked disruption of elastic fibers, pronounced fibrotic thickening of the adventitia and intimal thickening, all of which are causes of stenotic lesions.<sup>1,8,16</sup>



**Fig. 2.** Fluoroscopic evaluation of the patient shows abnormal movement of prosthetic valve leaflet (malfunction).

In our case atherosclerosis of the intima and interruption of elastic fibers was found, but these findings were misinterpreted as luetic arteritis.

Aneurysm formation can occur in patients without severely scarred changes in the aortic wall, because dystrophic calcification represents deposition of calcium in scarred media and intima. Therefore, the aorta with no or little calcification has a greater possibility of aneurysm formation in Takayasu's arteritis. In this case we had no information about the presence of calcification in the aortic wall in her previous study (about 11 yrs ago), but at this operation we encountered severe calcification which involved the ascending, transverse arch, and descending aorta.

Kumar et al<sup>10</sup> reported that the aneurysmal formation in Takayasu's arteritis was associated with a higher incidence of aortic valve regurgitation, which may result from enlargement of the ascending aorta and an elevated ESR. In our case the ESR always was high.

At the first operation, which was AV replacement, there was no dilation in the ascending aorta but severe inflammation of the aortic wall and thickening of cusps was present.

By showing arterial wall changes, cross sectional imaging techniques such as CT scan play an important role in the early diagnosis of Takayasu's arteritis.<sup>1-3</sup>

Although the clinical and radiologic features of the acute (early) phase of Takayasu's arteritis differ from those of the late (occlusive or pulseless) phase, the two phases of the disease are not clearly different, because of the insidious onset of the disease and the relapse of arteritis in some patients. In some patients with acute phase Takayasu's arteritis, the significant feature is wall thickening. Some previous studies reported pathologic evidence of severe inflammation in the media and adventitia.<sup>1,12,13</sup> Pathologic examination in this case showed infiltration of round cells in the media and adventitia. Several studies have suggested that systemic hypertension is related to increasing aneurysmal size.<sup>14</sup> In this case, systemic

hypertension has been found from about 11 years ago, too.

### Conclusion

In conclusion, because aneurysmal formation in Takayasu's arteritis may occur with variable incidence, close follow-up of these patients should be done with CT scan. Aortic calcification may not prevent aneurysmal formation, so the patients with aortic calcification should be followed as other cases with Takayasu's arteritis.

### References

1. Matsunaga N, Hayashi K, Sakamoto I, Ogawa Y, Matsumoto T. Takayasu arteritis: radiologic manifestations and diagnosis. *Radiographic* 1997; 17: 579-596 [Abstract].
2. Tanugawa K, Keguchi K, Kitamura Y, et al. Magnetic resonance imaging detection of aortic and pulmonary artery wall thickening in acute stage of Takayasu arteritis: improvement of clinical and radiologic findings after steroid therapy. *Arteritis Rheum* 1992; 35: 476-480 [Medline].
3. Yamada I, Nakagawa T, Himeno Y, Numano F, Shibuya H, Takayasu arteritis: evaluation of the thoracic aorta with CT angiography. *Radiology* 1998; 209: 103-109 [Abstract].
4. Yamato M, Lecky JW, Hiramatsu K, Kohda E. Takayasu arteritis: radiographic and angiographic findings in 59 patients. *Radiology* 1986; 161: 329-334 [Abstract].
5. Lande A, Bard R, Rossi P, Passariello R, Castruzzi A. Takayasu's arteritis: a world-wide entity. *N Y State J Med* 1976; 76: 1477-1482 [Medline].
6. Ishikawa K, Maetani S. Long-term outcome for 120 patients with Takayasu's disease: clinical and statistical analyses of related prognosis factors. *Circulation* 1994; 90: 185-1860 [Abstract].
7. The Aortitis Syndrome Research Committee of Japan organized by the Ministry of Health and Welfare. A report of the survey of aortitis syndrome in Japan [in Japanese]. Tokyo: Ministry of Health and Welfare, 1993: 8-10.
8. Eijun S, Ichiro S, Kuniaka H. Aortic aneurysms in patients with Takayasu's arteritis. *AJR* 200; 175: 1727-1733.
9. Sharms S, Rajani M, Kamalakar T, Kumar A, Talwar KK. The association between aneurysm formation and systemic hypertension in Takayasu's arteritis. *Clin Radiol* 1990; 42: 182-187 [Medline].
10. Kumar S, Subramanian R, Raviyamandalam K, et al. Aneurysmal form of aortoarteritis (Takayasu's disease): analysis of thirty cases. *Clinical Radiol* 1990; 42: 342-347 [Medline].
11. Nasu T. Pathology of pulseless disease: a systemic study and critical review of twenty-one autopsy cases reported in Japan. *Angiology* 1963; 14: 225-235.
12. Park JH, Chung JW, Im JG, Kim SK, Park TB, Han MC. Takayasu arteritis: evaluation of mural changes in the aorta and pulmonary artery with CT angiography. *Radiology* 1995; 196: 89-93 [Abstract].
13. Virman R, Lande A, McAllister HA Jr. Pathological aspects of Takayasu's arteritis. In: Lande A, Berkman YM, McAllister HA Jr, (eds). *Aortitis: Clinical, Pathologic, and Radiologic Aspects*. New York: Raven, 1986: pp. 55-79.
14. Hirose Y, Hamada S, Takamiya M, Imakita S, Naito H, Nishimura T. Aortic aneurysms: growth rates measured with CT. *Radiology* 1992; 185: 249-252 [Abstract].