

## Concealed Left Atrial Membrane: A Pitfall in the Diagnosis of Cor Triatriatum

Majid Maleki MD, Anita Sadeghpour MD, Alireza Moarref MD, Feridoun Noohi MD, Ali Sadeghpour Tabaei MD, Mahshid Ojaghi MD, Maryam Esmailzadeh MD, Niloofar Samiei MD, Ahmad Mohebbi MD  
and Goldis Malek PhD

### Abstract

Cor triatriatum is an unusual congenital anomaly that is probably not as rare as previous reports have indicated. Herein we describe a case of left atrium membrane with multiple large atrial septal defects mimicking cor triatriatum in the absence of pulmonary venous obstruction. We hypothesized that left atrium membrane, when associated with other cardiac lesions, masked pulmonary venous obstruction and that failure to recognize this structure might result in pulmonary venous obstruction at the time of surgical repair of the primary defect and consequently poor surgical outcome (*Iranian Heart Journal 2008; 9 (1):61 -63*).

**Key words:** cor triatriatum ■ left atrial membrane ■ atrial septal defect

### Case report

A 55-year-old woman presented with progressive dyspnea and exhaustion on exertion and occasional chest pain for the past year. On physical examination, systolic ejection murmur and splitting of S2 were noted in the left second intercostals space. S3 and S4 gallop was absent, and the lung examination was unremarkable.

The patient's electrocardiogram was normal. Chest X-ray revealed right ventricular enlargement with an increased pulmonary blood flow.

Transthoracic echocardiography revealed a dilated right ventricle and a large ostium secundum atrial septal defect (ASD) as well as a non-obstructive membrane in the left atrium.

Transesophageal echocardiography showed an aneurysm of the interatrial septum (Fig. 1) with multiple defects (Fig. 2) and a perforated membrane in the left atrium originating from the Warfarin ridge, which attaches to the septum primum. No obstruction was seen in the color and Doppler studies (Fig. 3). These observations were suggestive of non-obstructive cor triatriatum.

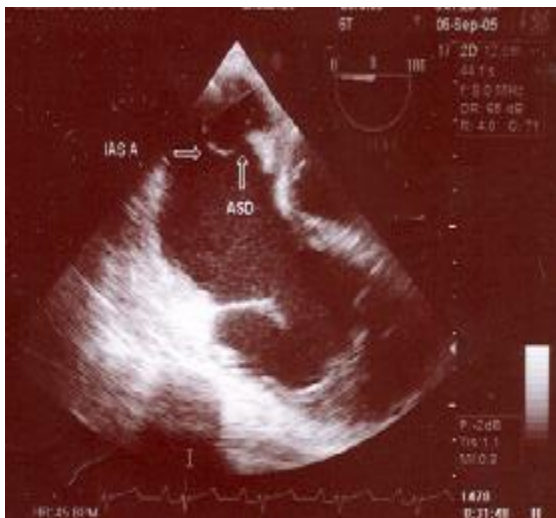
Cardiac catheterization was performed, revealing an ASD with significant left-to-right shunt, no gradient in the left atrial cavity, and no significant pulmonary hypertension.

ASD was repaired surgically with a pericardial patch, and the left atrial membrane was removed.

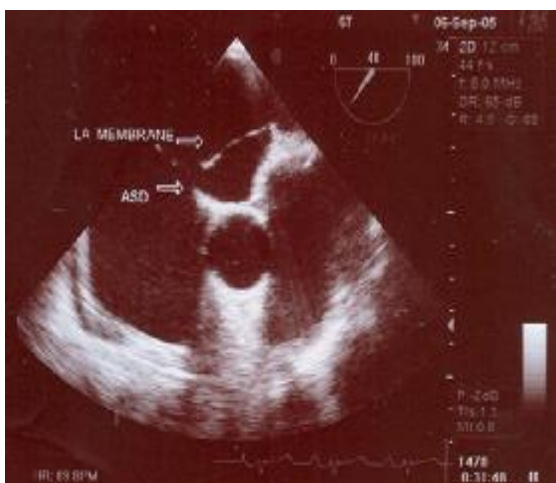
Received Apr, 21 2006; Accepted for publication Apr 24, 2008.

From the Echocardiography Lab, Department of Cardiovascular Medicine, and Department of Cardiovascular Surgery, Shaheed Rajaie Cardiovascular Medical Center, Vali Asr Ave., Mellat Park, Tehran, Iran.

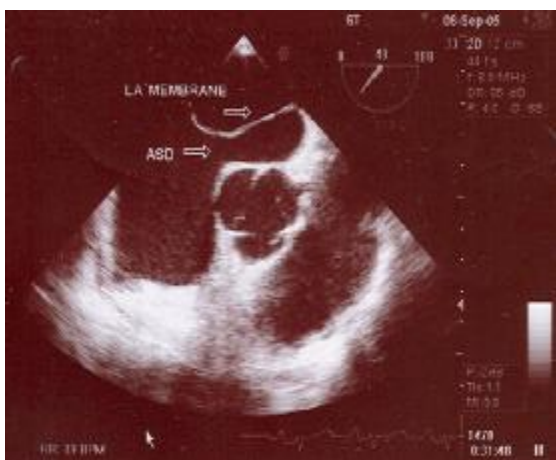Address correspondence to: M. Maleki, MD, Department of Cardiology, Shaheed Rajaie Cardiovascular Medical Center (RHC), Tehran, Iran.  
Tel.: 22055594



**Fig. 1.** Transesophageal image of interatrial septal aneurysm



**Fig.2.** Transesophageal image of left atrial membrane and multiple atrial septal defects



**Fig. 3.** Transesophageal image showing left atrial membrane attachment to septum primum and Warfarin ridge

### Discussion

Cor triatriatum and supra-valvar mitral ring are congenital heart diseases in which the left atrial membrane produces a barrier to the left ventricular inflow. Typically these defects occur as isolated anomalies with manifestations of pulmonary venous obstruction, although this is not always the rule.

A major difficulty encountered in diagnosing left atrium membrane is that when it is associated with another cardiac lesion, pulmonary venous obstruction is frequently absent or masked.

The first mechanism is that the cross-sectional area of the membrane openings may be large enough such that no gradients occur.

The second mechanism is the presence of an atrial septal defect that decompresses the pulmonary venous chamber and allows blood to escape into the right atrium.

In cor triatriatum, the left atrium is subdivided into dorsal and ventral chambers by an abnormal fibromuscular diaphragm.<sup>1</sup> The dorsal chamber usually receives the pulmonary veins and the ventral chamber usually communicates with the mitral valve and the left atrial appendage. Interatrial communications may be present between either chambers or the right atrium. An atrial septal defect has been found in 70-80% of cases, and this defect can communicate with either or both chambers. Other associated defects include AV septal defect, coarctation of the aorta, anomalous pulmonary venous return<sup>3</sup> and persistent LSVC.<sup>4</sup>

A prevailing theory of embryogenesis of cor triatriatum implicates the failure of the common pulmonary vein to incorporate into the left atrium. Alternatively, it has been suggested that an abnormal growth of the septum primum accounts for cor triatriatum.<sup>5</sup>

Our patient presented initially with atrial septal defect. Cardiac catheterization confirmed the diagnosis but only echocardiography revealed the left atrium membrane.

### Conclusion

In all patients with left atrial membrane, failure to recognize the structure may result in pulmonary venous obstruction at the time of surgical repair of the primary defect. In some case reports, patients who had undergone surgical repair for their congenital heart defects before left atrium membrane were firmly diagnosed had a poor surgical outcome.<sup>2</sup>

The correct diagnosis may be facilitated by a high index of suspicion that a left atrial membrane may complicate other congenital heart defects, even without evidence of pulmonary venous obstruction. This type of left atrial membrane could be called “non-obstructing cor triatriatum”.

### References

1. Niwayama G. Cor triatriatum. *Am Heart J* Feb 1960; 59: 291-302.
2. Jacobstein MD, Hirschfield SS. Concealed left atrium membrane: pitfalls in the diagnosis of cor triatriatum. *Am J Cardiol* 1982; 49: 780-785.
3. Snider A. *Echocardiography in Pediatric Heart Disease*. 2<sup>nd</sup> edition, Baltimore, C. V. Mosby Co., 1992.
4. Farid G, Bernard H. A proposed pathogenesis of cor triatriatum. *Am Heart J* 1977; Nov. 94; 5: 618-626.
5. Moss and Adam's *Heart Disease in Infants, Children and Adolescents*. 6th edition, Philadelphia, Lippincott. 2000.