

Isolated Ventricular Non-Compaction: Case Report and Review of Literature

M. Esmailzadeh, MD, A. Zoroufian, MD and M. Momtahn,* MD

Abstract

Isolated ventricular non-compaction is a rare congenital cardiomyopathy, manifested morphologically as prominent myocardial trabeculations and deep recesses that communicate with the ventricular cavity. Heart failure is the most common presenting condition. This report is illustrative of isolated ventricular non-compaction in a 51-year-old male. The diagnosis was made when he presented with congestive heart failure (*Iranian Heart Journal 2006; 7 (1): 60-63*).

Key words: left ventricular cardiomyopathy ■ non-compaction ■ heart failure

Isolated ventricular non-compaction (IVNC) is a rare congenital cardiomyopathy manifested morphologically as prominent myocardial trabeculations and deep inter-trabecular recesses that communicate with the ventricular cavity without evidence of communication to the epicardial coronary artery system. The condition is thought to arise from abnormal morphogenesis involving intrauterine arrest of normal compaction of the myocardium. Clinical manifestations include congestive heart failure (CHF), arrhythmias and cardio-embolic events.

Case report

A 51-year-old man was admitted to our hospital in January 2005 with progressive heart failure.

On admission, he had dyspnea and orthopnea and mild chest discomfort.

On physical examination there was a soft S_1 and loud S_2 (p_2) sound, with a grade III/VI systolic murmur at the apex and lower left sternal border, bilateral fine basilar rales, mild hepatomegaly and +1 pitting edema in the extremities. EKG showed atrial fibrillation rhythm, mild ST-depression in I, AVL, V5 and V6, with poor R progression in the anterior leads (Fig.1).

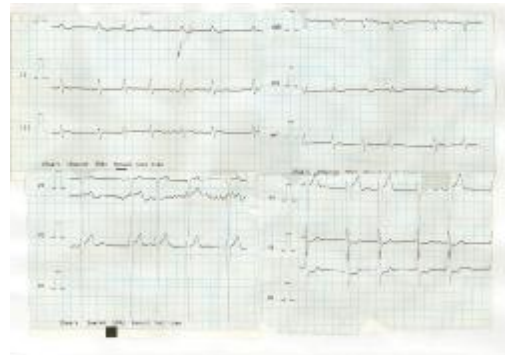


Fig. 1: EKG shows poor-R-progression and ST-T changes.

Received Aug. 26, 2005; Accepted for publication Nov. 30, 2005.

From the Department of Echocardiography and *General Cardiology, Shaheed Rajaei Cardiovascular Medical Center, Iran University of Medical Sciences, Tehran, Islamic Republic of Iran.

Correspondence to: M. Esmailzadeh, MD, Dept. of Echocardiography, Shaheed Rajaei Cardiovascular Medical Center, Vali Asr Avenue, Tehran, Iran.

Tel: 021 23922494

email: m_eszadeh@yahoo.com

Chest X-ray showed significant cardiomegaly (Fig. 2). Transthoracic echocardiography was performed for evaluation of underlying causes and showed prominent myocardial trabeculations in the left ventricle (LV), with deep inter-trabecular recesses (Fig. 3) that communicated with the LV cavity; blood flow into the recesses was demonstrated by color Doppler examination, which is pathognomonic for IVNC.

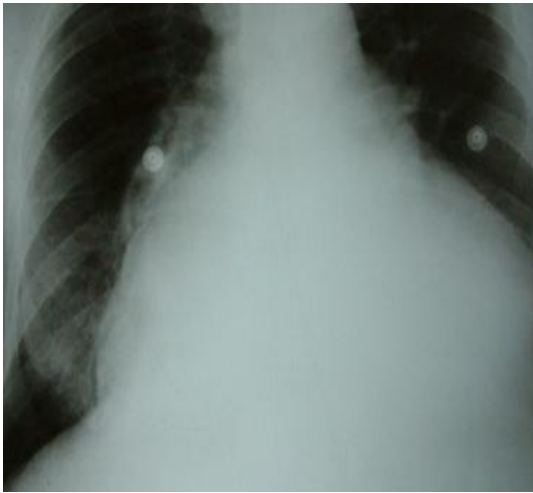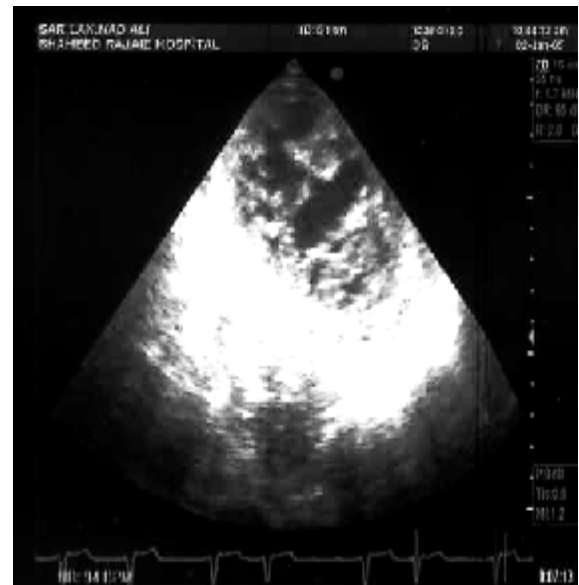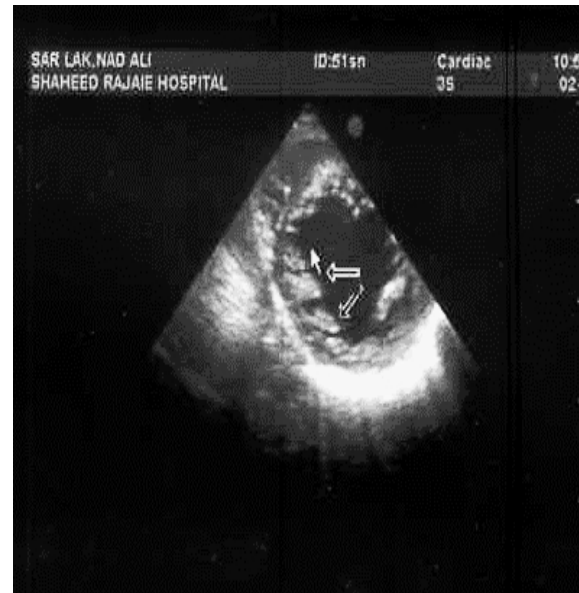


Fig. 2. CXR shows significant cardiomegaly.

There was severe LV enlargement with global hypokinesia and severely reduced LV systolic function with estimated LV ejection fraction of about 10-15%. There was also severe diastolic dysfunction (restrictive pattern) with severe functional mitral regurgitation (MR) and tricuspid regurgitation (TR). The right ventricle was structurally normal and was slightly enlarged with near normal systolic function; calculated pulmonary arterial pressure was about 75-80 mmHg. He had no symptoms until the age of 48 years, at which time he developed progressive left heart failure. There was no family history of heart disease or cardiac risk factors. The results of multiple echocardiographic

examinations two years before were interpreted as dilated cardiomyopathy. Coronary angiography did not show any coronary anomaly or significant coronary stenosis. The patient was treated with digoxin, diuretics, ACE inhibitors and warfarin and was stabilized before discharge.

a



b

Fig. 3. Short axis views from papillary muscle (a) and apical plane (b) of the LV, showing hypertrabeculated LV with deep intertrabecular recesses.

Discussion

Pathogenesis

During a period of normal embryonic development the myocardium exists as a loose meshwork of interwoven myocardial fibers that form trabeculae with deep inter-trabecular recesses through a process of compaction of the myocardium.^{1,3} The inter-trabecular recesses are transformed into the coronary circulation. Embryonic arrest of the process (normally in the first month of fetal life) leads to the persistence of prominent myocardial trabeculations with deep recesses that communicate with the LV cavity in the absence of coexisting congenital heart abnormalities. This condition is termed IVNC. The cause of IVNC has not been completely determined; probably mutations in the gene G4,5 on the Xq28 chromosomal region are responsible,⁴⁻⁷ and both sporadic and familial causes have been described for this disease state.^{1,5} Today, it is categorized as an unclassified cardiomyopathy.⁸

Clinical manifestations

Isolated ventricular non-compaction may affect both sexes, although there is a male preponderance.^{1,4,9} Patients may be asymptomatic, however clinical presentation if present can include CHF, arrhythmias, and cardio-embolic events.^{4,5} Congestive heart failure is the most common presenting condition. CHF can be a result of either systolic or diastolic ventricular dysfunction. Diastolic dysfunction is probably a result of the abnormal ventricular trabecular structure, causing impaired relaxation and filling. The cause of systolic dysfunction is less clear; chronic myocardial ischemia due to coronary micro-circulatory dysfunction has been recently suggested as a possible mechanism.¹¹

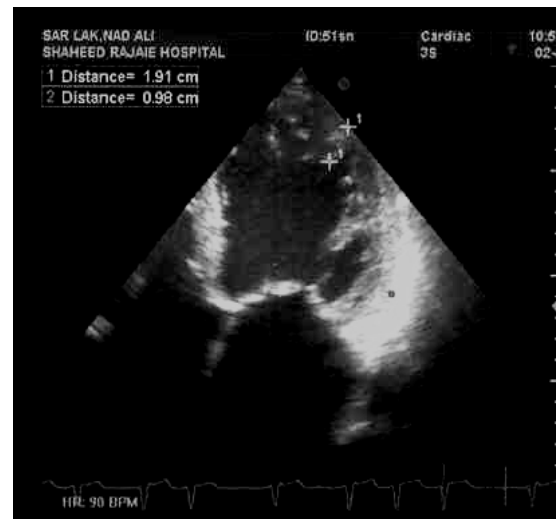

Fig. 4. Apical 4-chamber view shows non-compacted /compacted ratio > 2.

Diagnosis

Echocardiographic findings are often diagnostic. Presence of more than three trabeculations within one image plane, especially from the insertion of the papillary muscles are a practically useful criterion.^{1,3,6,9}

The affected myocardium shows a thick non-compacted endocardial layer and a thinner compacted epicardial layer (Fig. 4).

LV mass was estimated both with and without the incorporation of trabeculations in the short-axis view. A maximal end-systolic ratio of non-compacted layer to compacted layer of 2 or more considered diagnostic, or trabecular mass/total mass >20% may be a useful index in diagnostic measures. Presence of deep inter-trabecular recesses with direct blood flow from the ventricular cavity into the recesses demonstrable in color Doppler imaging is also diagnostic.⁹⁻¹²

The diagnosis of IVNC can be made in the presence of these echocardiographic features.

In the absence of co-existing congenital abnormalities the LV is affected primarily, the apical, lateral and inferior segments are commonly involved, involvement of the midventricular anterior wall and septum

and the basal segments is much less frequent.¹³ The RV may also be affected but differentiation from normal trabeculations may be difficult. LV systolic and diastolic dysfunctions are commonly present. The morphological appearance of IVNC has also been described on angiography, computed tomographic and magnetic resonance imaging. ECG findings are abnormal in 74% of the patients and showed most frequently ST and T changes and signs of LVH.

Management and Prognosis

There is no specific treatment. The treatment is directed at the patient's symptoms and complications and includes all that is available for the treatment of heart failure. A more aggressive approach to diagnosis and treatment of ventricular arrhythmias is considered, and because of the higher risk of thrombus formation within the intra-trabecular recesses prophylactic anticoagulation may be justified. In some cases heart transplantation may be considered. All symptomatic patients have a high risk of mortality and morbidity.^{1,4,6} For patients diagnosed at the asymptomatic stage, the short-term to medium-term prognosis is favorable but progressive ventricular dysfunction is common.⁶

References

1. Chin TK, Perloff JK, Williams RG, Jue K, Mohrmann R. Isolated non-compaction of left ventricular myocardium: A study of eight cases. *Circulation* 1990; 82: 507-13.
2. Agmon Y, Connolly HM, Olson LJ, Khandheria BK, Seward JB. Non-compaction of the ventricular myocardium. *J Am Soc Echocardiogr* 1999; 12: 859-63.
3. Jenni R, Oechslin E, Schneider J, Jost CA, Kaufmann PA. Echocardiographic and pathoanatomical characteristics of isolated left ventricular non-compaction; a step towards classification as a distinct cardiomyopathy. *Heart* 2001; 36: 493-500.
4. Riter M, Oechslin E, Sutsch G, Attenhofer C, Scheider J, Jenni R. Isolated non-compaction of the ventricular myocardium in adults. *Mayo Clin Proc* 1997; 72: 26-31.
5. Ichida F, Hamamichi Y, Miyawaki T, et al. Clinical features of isolated non-compaction of the ventricular myocardium. *J Am Coll Cardiol* 1999; 34: 233-40.
6. Bleyl SB, Mumford BR, Brown-Harrison MC, Pagotto LT, Carey JC, Pysker TJ, et al. Xq28-linked non-compaction of the left ventricular myocardium: prenatal diagnosis and pathologic analysis of affected individuals. *Am J Med Genet* 1997; 72:257-65.
7. Richardson P, McKenna W, Bristow M, et al. Report of the 1995 World Health Organization /International Society and Federation of Cardiology Task Force on the definition and classification of cardiomyopathies. *Circulation* 1996; 93: 841-2.
8. Maltagliati A, Pepi M. Isolated non-compaction of the myocardium: multiplane transesophageal echocardiography diagnosis in an adult. *J Am Soc Echocardiogr* 2000; 13: 1047-9.
9. Jenni R, Wyss CA, Oechslin EN, Kaufmann PA. Isolated ventricular non-compaction is associated with coronary microcirculatory dysfunction. *J Am Coll Cardiol* 2002; 39: 450-4.
10. Elshershari H, Okutan V, Celiker A. Isolated non-compaction of the ventricular myocardium. *Cardiol Young* 2001; 11: 472-475.
11. Buonanno C, Variola A, Dander B, Gabaldo S, Marafioti V. Isolated non-compaction of the myocardium: an exceedingly rare cardiomyopathy; a case report. *Ital Heart J* 2000; 1: 310-5.
12. Oechslin EN, Attenhofer Jost CH, Rojas JR, Kaufmann PA, Jenni R. Long-term follow-up of 34 adults with isolated left ventricular non-compaction; A distinct cardiomyopathy with poor prognosis. *J Am Coll Cardiol* 2000; 36: 493-500.
13. Duru F, Candianas R. Non-compaction of ventricular myocardium and arrhythmias. *J Cardiovasc Electrophysiol* 2000; 11: 493.