

Valve-Patch for Closure of Large Ventricular Septal Defect with Pulmonary Artery Hypertension

A. Afrasiabi MD, M. Pezeshkian MD, B. Rastkar MD,
M. Samadi MD, N. Safaei MD and H. Montazergaem MD

Abstract

Objective - Decision making for closure of large ventricular septal defect (VSD) with increased pulmonary vascular resistance (PVR) sometimes is difficult. In this prospective study, we report our experience in patients undergoing closure of large VSD with a valve-patch.

Methods- Between March 1998 and December 2004, acyanotic patients with large VSD and pulmonary artery hypertension were selected for surgery. In all the patients, Gortex patch material was used, and a longitudinal slit (5-8 mm) was made in the middle part of it. A pericardial piece was sewn around the slit on one side of the Gortex patch except in the upper part. Usually via the right atrial approach, the VSD was closed with trimmed Gortex patch with the pericardial valve-patch located on the left ventricular side, allowing it to open for probable right to left shunt.

Results- Sixteen patients with a mean age of 7 ± 5.7 years and PVR of 9.6 ± 3.8 Wood units underwent operation. All the patients were weaned off cardiopulmonary bypass successfully and sedated for at least 18-24 hours. Echocardiography on the same day of operation revealed right to left shunt in 6 cases. Two patients died in the early postoperative period. One child died due to frequent episodes of pulmonary hypertensive crisis and the other with persistent severe pulmonary hypertension and systemic low oxygen saturation. In three years' follow-up, PVR gradually regressed except in one case, in which PVR increased with right-to-left shunt and cyanosis.

Conclusion- Valve patch technique in severe pulmonary artery hypertensive cases is a promising technique to decrease morbidity and mortality; however, in sustained or elevated PVR it may have deleterious effects in the early and late postoperative periods (*Iranian Heart Journal* 2006; 7 (1): 6-10).

Key words: ventricular septal defect ■ pulmonary hypertension

Large ventricular septal defect (VSD) in infants may result in congestive heart failure. With increasing age and continuing left-to-right shunt, pulmonary artery pressure and pulmonary vascular resistance may increase.¹

Depending on the response of the pulmonary vascular to the increased flow and pressure, pulmonary vascular changes may develop.

Unoperated large VSDs are often complicated by irreversible changes in the pulmonary vascular bed. Closure of large VSDs with increased pulmonary vascular

resistance (PVR) is associated with significant morbidity and mortality.²

In this study, we report our experience in closure of large VSDs with severe pulmonary hypertension by using a novel valve-patch.

Methods

Between March 1998 and December 2004, 16 patients with large VSD and increased pulmonary vascular resistance were included for study.

All the patients were evaluated preoperatively by history and physical examination, chest roentgenogram, electrocardiography, echocardiography and cardiac catheterization. Generally, patients with clinical cyanosis were excluded from surgery. In cardiac catheterization, complete hemodynamic data and oximetry were determined. Pulmonary and systemic flow and resistances at rest and during use of high oxygen flows for a period of 10 minutes were measured.

The decision for surgery was based on the judgment of the cardiologist and the cardiac surgeon and acceptance of risk by the patient's family.

Operative procedure

All the surgical procedures were performed by one surgeon. Cardiopulmonary bypass (CPB) with moderate hypothermia and cold blood cardioplegia was used in all the patients. Before operation, VSD size and location was determined by echocardiography.

Simultaneously with preparation of patients for sternotomy and cannulation, the VSD patch was constructed from Gortex (W.L. Gore, Newark, Delaware) and a piece of the patient's pericardium. Depending on VSD size and PVR, a central perpendicular slit about 5-8 mm in length was created in the Gortex patch and covered by a quadrangular piece of autologous pericardium which was continuously sutured around three-fourths of the slit to provide orientation of flow to the aorta. The operative approach varied according to location of the VSD, but was by preference through the right atrium. Subpulmonic and subarterial VSDs were repaired through the main pulmonary artery, and right ventricular infundibulum. VSDs were closed with trimmed Gortex patch with the pericardial aspect located on the left ventricular side to allow for opening for probable right-to-left shunt (Fig. 1).

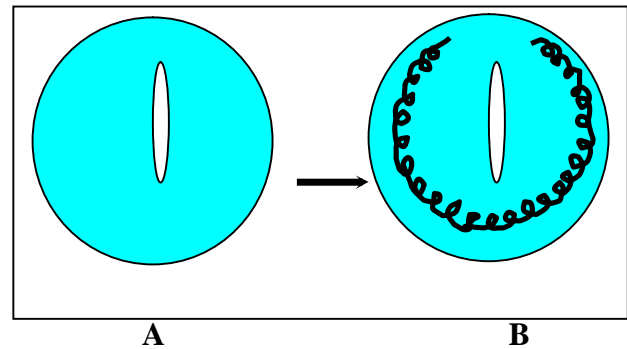


Fig. 1. A, creation of slit in the middle part of the trimmed Gortex patch. B, autologous pericardial patch was sewn around the slit on one side of the Gortex patch, except in the upper part.

After weaning from CPB, modified ultrafiltration was used and vasodilators, usually milrinone, were started. All the patients were sedated for 18-24 hours after operation with fentanyl in an attempt to maintain mild-to-moderate hypocarbia. On the same day of operation, cardiac function and valve patch were assessed for any shunt by transthoracic echocardiography. All the patients were followed up by echocardiography at the time of discharge, and one, three and six months later for evaluation of pulmonary artery pressure and probable shunt. Results were expressed as mean \pm standard deviation.

Results

The mean age at surgery was 7 ± 5.7 years (range 2 to 22 years), and twelve patients (76%) were male. One patient had Down's syndrome with secundum atrial septal defect, and two others had moderate-sized patent ductus arteriosus. Mean PVR was 9.6 ± 3.8 Wood units (range 6.7 to 16.8). Following the administration of oxygen, an increase in the left-to-right shunt and reduction in PVR was recorded in 3 patients.

The mean PVR at pre- and post-oxygen administration was 10.8 ± 3.6 and 7.4 ± 2 Wood units, respectively. 70% of the patients had perimembranous VSD. Preoperative hemodynamic data are given in Table I.

Table I. Preoperative hemodynamic data of patients

Ao systolic pressure (mmHg)	109±15
PA systolic pressure (mmHg)	95±13
Ao oxygen saturation (%)	92±2.6
Qp:Qs	2±0.76
PVR (wood units)	9.6±3.8
SVR (wood units)	24±8
PVR: SVR	0.4±0.14

Ao: aorta, **PA:** Pulmonary artery, **Qp: Qs:** ratio of pulmonary blood flow to systemic blood flow, **PVR:** Pulmonary vascular resistance, **SVR:** Systemic vascular resistance, **PVR:SVR:** ratio of pulmonary vascular resistance to systemic vascular resistance. All values are expressed as mean ± SD

All the patients were weaned off cardiopulmonary bypass successfully. Two patients died in the early postoperative period. One patient died on the third postoperative day due to multiorgan failure. Despite deep sedation on the ventilator, frequent episodes of pulmonary hypertensive crisis and convulsions occurred in this patient. The other died on the fifth postoperative day with persistent severe pulmonary artery hypertension, concomitant right-to-left shunt and low systemic oxygen saturation.

On the same day of operation, pulmonary hypertensive crises were monitored in 6 patients. In these cases, right-to-left shunt through the valve patch was detected by echocardiography. Except for those patients who died, the others had an apparently uneventful postoperative course. In the mean follow-up of 3.2 years (range 5 months to 6 years), one patient suffered from palpitation and cyanosis. This patient underwent surgery at the age of 10 years with a basal PVR of 9 Wood units and after 4 years, is in NYHA functional class III with echocardiographic and catheterization evidence of severe pulmonary hypertension and right-to-left shunt through the valve patch. Two other

patients 3 years after surgery are in NYHA functional class II with echocardiographic evidence of moderate pulmonary hypertension. They were operated on at the age of 18 and 22 years with a mean basal PVR of 7.1 Wood units. All the others are asymptomatic with normal or near normal pulmonary artery pressure.

Discussion

There are several surgical approaches to treat large VSD with severe pulmonary hypertension.³ Pulmonary artery banding was first described by Muller⁴ as a method for reducing large left-to-right shunt and improving survival. Operative mortality for this procedure was significant in small infants, and many of these patients have significant residual pulmonary artery deformity after reconstruction.⁵ Primary closure of VSD with fenestrated patch has been suggested as an alternative to two-stage management.² It has the advantages of one less procedure for the improvement of outcome in the early postoperative period, but with diminishing pulmonary artery pressure, the left-to-right shunt occurs with a risk of bacterial endocarditis. Unidirectional valve patch for closure of large VSD with pulmonary hypertension has been reported with reasonable morbidity and mortality.^{6,7} One-way shunt through the valvular patch is important in the early postoperative period. After operation, pulmonary hypertensive crisis may occur and can be associated with acute heart failure and death. It is vital to the patients to prevent refractory pulmonary artery hypertension with reducing risk of death. During these episodes, unloading the right ventricle is important, which can be achieved through the valvular patch with flow of blood from the right to left side. In our study, six patients experienced pulmonary hypertensive crisis with right-to-left shunt. Creation of a one-way shunt sometimes may have deleterious effects in the early and even late postoperative periods of patients with a sustained elevated PVR. In

comparison with bi-directional shunt in fenestrated patch, these patients have only right-to-left shunt, which may lead to low systemic oxygen saturation and long intubation time in the early postoperative period. In the late phase, persistent pulmonary hypertension may result in early cyanosis compared to “inoperable” patients with large VSD. One case in our series developed cyanosis 4 years after surgery. This patient, who had undergone surgery at the age of 10 years with a basal PVR of 9 Wood units, developed progressive pulmonary vascular disease with a right-to-left shunt through the valve patch.

When the patient’s PVR regressed and pulmonary artery pressure decreased, the pericardium in the valvular patch adhered to the Gortex to prevent left-to-right shunt. Because there is only a slit in the Gortex patch and pericardium is a flexible tissue, evidence of left ventricular outflow tract obstruction or pericardial aneurysm through the slit was not found in the follow-up.

The prognosis for patients undergoing closure of large VSD with increased pulmonary vascular resistance is dependent upon the age and PVR at presentation.^{1,8} Although the patients in our study were older with high PVR, surprisingly mortality occurred in younger children. One patient (2.5 years old) died on the third postoperative day with frequent episodes of pulmonary hypertensive crisis and the other (4 years old) died because of sustained elevated PVR with right-to-left shunt via the valve patch. This patient could not experience more than 90% arterial O₂ saturation. If nitric oxide had been available in our center, it might have improved oxygenation and hemodynamic indices in the short-term in these patients. Nevertheless, as Kannan⁹ reported, we think presumably rapid progression of PVR in younger children is a risk factor for significant morbidity and mortality compared to older patients with a similar elevation of PVR.

Surgery in older patients had a favorable outcome in our study. In the early postoperative period, pulmonary hypertensive episodes did not occur but arrhythmia was a common finding, which was tolerated well and controlled by medication. In comparison to younger children, PVR gradually regressed in these patients but did not reach normal levels of PVR with good exercise capability. It can be related to fixed histopathologic changes in the pulmonary vascular bed.

Extubation time after operation is a challenging matter in these patients. Pulmonary vasoconstrictive effects of cardiopulmonary bypass and exacerbation of pulmonary vasoconstriction in the early postoperative period are well appreciated.^{10,11} Sometimes the development of pulmonary hypertensive episodes mandates delayed extubation.¹² Novick et al.⁷ used a flap-valve patch for closure of VSD with increased pulmonary vascular resistance in children. They reported rapid extubation of children to prevent adverse events. In our experiences with early extubation, pulmonary hypertensive episodes occurred in 3 cases, which led to right-to-left shunt and reintubation. Owing to hazards of reintubation and pulmonary hypertensive crisis, we abandoned rapid extubation to support the respiratory system on the first postoperative day.

In conclusion, the valve-patch in severe pulmonary artery hypertensive cases is a promising technique to decrease morbidity and mortality; however, in sustained or elevated PVR, it may have deleterious effects in the early and late postoperative periods.

References

1. Rabinovitch M, Keane JF, Norwood WI, Castaneda AR, Reid L. Vascular structure in lung tissue obtained at biopsy correlated with pulmonary hemodynamic findings after repair of congenital heart defects. *Circulation* 1984; 69:655-67.
2. Novick WM, Gurbuz AT, Watson DC, et al. Double patch closure of ventricular septal defect with increased pulmonary vascular

- resistance. *Ann Thorac Surg* 1998; 66:1533-8.
3. Kirklin JW, Barratt-Boyes BG. Ventricular septal defect. In: *Cardiac Surgery*, 3rd ed. Churchill-Livingstone, pp.851-897, 2003.
 4. Hallman GL, Cooley DA, Bloodwell RD. Two-stage surgical treatment of ventricular septal defect: Results of pulmonary artery banding in infants and subsequent open-heart repair. *J Thorac Cardiovasc Surg* 1966; 52: 674.
 5. Dobell ARC, Murphy DA, Poirier NL, Gibbons JE: The pulmonary artery after debanding. *J Thorac Cardiovasc Surg* 1973; 65:1.
 6. Zhou Q, Lai Y, Wei H, Song R, Wu Y, Zhang H. Unidirectional valve patch for repair of cardiac septal defects with pulmonary hypertension. *Ann Thorac Surg* 1995; 60:1245-9.
 7. Novick WM, Sandoval N, Lazorhysynets VV, Castillo V, Baskevitch A, et al. Flap valve double patch closure of ventricular septal defects in children with increased pulmonary vascular resistance. *Ann Thorac Surg* 2005; 79:21-8.
 8. Blackstone EH, Kirklin JW, Bradley EL, DuShane JW, Appelbaum A. Optimal age and results in repair of large ventricular septal defects. *J Thorac Cardiovasc Surg* 1976; 72: 661-79.
 9. Kannan BR, Sivasankaran S, Tharakan JA, et al. Long-term outcome of patients operated for large ventricular septal defects with increased pulmonary vascular resistance. *Indian Heart J* 2003; 55: 161-6.
 10. De Souza CA, Spyt TJ. Release of vasoactive substance during cardiopulmonary bypass. *Ann Thorac Surg* 1992; 56:397-8.
 11. Komai H, Yamamoto F, Tanaka K, et al. Increased lung injury in pulmonary hypertensive patients during open heart operations. *Ann Thorac Surg* 1993; 55:1147-52.
 12. Komai H, Yamamoto F, Tanaka K, Yagihara T, Kawashima Y. Prevention of lung injury during open-heart operations for congenital heart defects. *Ann Thorac Surg* 1994; 57:134-40.