

Atrial Septal Aneurysm Concomitant with Severe Mitral Stenosis

Saeed Hosseini MD, Mehdy Hadadzadeh MD, Alireza Alizadeh Ghavidel MD,
Rostam Esfandiari MD

Abstract

An atrial septal aneurysm is an uncommon abnormality and may be the origin of thromboembolic events. We would like to present an unusual case of the septal abnormality with mitral stenosis and history of thrombo-embolic cerebrovascular accident (*Iranian Heart Journal 2009; 10 (1):55-57*).

Key words: atrial septal aneurysm ■ cerebrovascular accident

Atrial septal aneurysm (ASA) is a rare but well-recognized cardiac abnormality of uncertain clinical significance.¹⁻⁶ ASA has been reported as an unexpected finding during autopsy¹ but may also be diagnosed in living patients by echocardiographic techniques.² ASA formation can be secondary to interatrial pressure differences but may also be a primary malformation involving the region of the fossa ovalis or the entire septum. ASA may be an isolated abnormality but is often found in association with other structural cardiac abnormalities, e.g., mitral valve prolapse^{7,8} or atrial septal defects.⁹ Several reports suggest a possible link between ASA and cardiogenic embolism in patients with otherwise unexplained ischemic stroke. We present an uncommon association of ASA with severe mitral stenosis (MS) and stroke.

Case report

A 44 year-old lady presented with shortness of breath for 3 months.

She was otherwise healthy until 2 years ago, when a thromboembolic cerebrovascular accident (CVA) occurred. Her past medical history was negative for other medical diseases.

Her vital signs were HR: 102/min. irregular, BP: 100/60 mm Hg, RR: 16/min. The positive findings in physical examination included an opening snap, mid-diastolic decrescendo murmur, S3 and right arm plegia grade 3. Preoperative laboratory values were within normal limits and the electrocardiogram showed atrial fibrillation (AF). No abnormality was found in chest X-ray. Transthoracic and transesophageal echocardiographies (TTE and TEE) revealed severe mitral stenosis (MS) with an estimated valve area of 0.9 cm² and some degrees of leaflet and annular calcification (echocardiographic score: 8-9). The left atrium (LA) was moderately enlarged (5 x 4.5 cm). In addition, the 2-D echocardiographic windows showed a large atrial septum aneurysm (29 x 26 mm) without any septal defect (Fig.1).

Received May 8, 2008; Accepted for publication Aug. 21, 2008.

From the Dept. of Cardiovascular Surgery and Cardiology, Shaheed Rajaei Cardiovascular Medical Center, Mellat Park, Vali Asr Ave. Tehran, Iran; Correspondence to: S. Hosseini, MD, Dept. of Cardiovascular Surgery, Shaheed Rajaei Cardiovascular Medical Center, Mellat Park, Vali Asr Ave. Tehran, Iran.
Tel : +982123922589

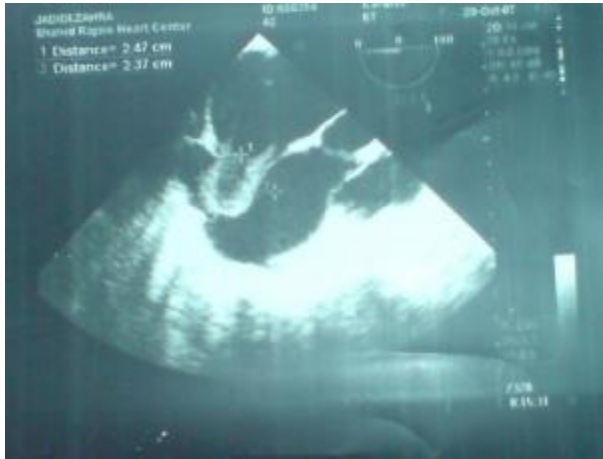

Fig. 1. Pre-operative transesophageal echocardiographic view.

During the diastolic phase the aneurysm bulged into the right atrium. No other pathology in the other heart valves or chambers was revealed. Estimated left ventricular ejection fraction was 45%, pulmonary artery pressure was 40mmHg and right ventricle function was reported as being within normal range. Selective coronary angiography showed normal coronary arteries.

Surgical Technique

Under general anesthesia, a standard median sternotomy was done and the pericardium was opened. After heparin infusion (3mg/kg), ascending aorta and bicaval cannulation was performed. After establishment of total cardiopulmonary bypass under normothermia, cardiac arrest was induced using antegrade and retrograde blood cardioplegia. Left and right atriotomies were done and the mitral valve, atrial chambers and septum were evaluated precisely. The mitral valve was involved with a rheumatic process and the thickened, calcified and destroyed mitral leaflets precluded the possibility of mitral repair. The atrial septum was aneurysmal and protruded into the right atrium. The base of the aneurysm was 25mm. After excision of both mitral leaflets, a 29mm mechanical prosthesis was inserted using interrupted

sutures. After excision of septal tissue involved with aneurysm, the resultant defect (30 x 30mm) was repaired with a fresh non-treated autologous pericardial patch using running 4-0 polypropylene sutures. The heart chambers were de-aired and atriotomy incisions repaired. The patient was weaned from CPB without inotropic support.

After hemostasis and leaving two drains in the mediastinal cavity and pericardial sac, the sternum was closed. The patient was extubated eight hours after arrival in the ICU. She made an uneventful recovery thereafter and hospital stay was 8 days. The function of the mitral prosthesis was normal on post-operative echocardiography and there was no residual ASD. Trans-mitral mean gradient was 2mmHg and LVEF was estimated at 45%.

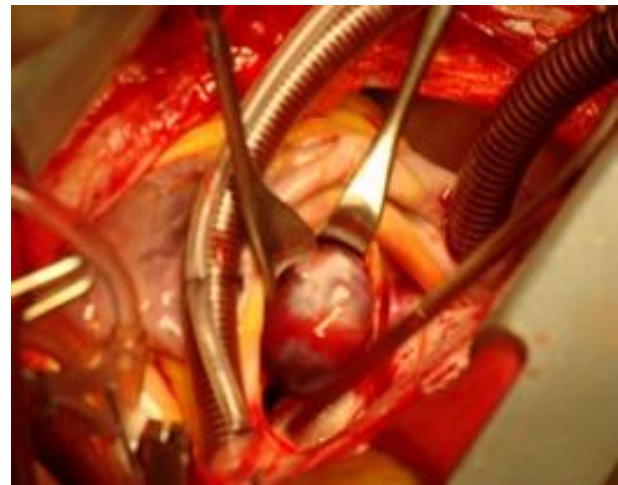


Fig. 2. Surgical view of the IAS aneurysm.

Discussion

Since the first report by Gallet et al.⁵ in 1985, several echocardiographic studies have suggested that an ASA may behave as a possible cardioembolic source leading to ischemic stroke, particularly when it is associated with a patent foramen ovale (PFO).⁶⁻¹⁰ ASA is an uncommon lesion, with a prevalence of 0.22% in a large prospective

study with TTE⁶, 3%–8% in studies with TEE^{8,10} and 1% in autopsies.¹² ASA is often associated with other cardiac abnormalities, including PFO, mitral valve prolapse, and atrial septal defect.⁹ Because an interatrial shunt, such as a small ASD or a PFO, has been noted in 54%–85% of patients with ASA,^{9,10} paradoxical embolism may be one potential mechanism related to stroke. Another possible mechanism is that an ASA itself may be thrombogenic because a thrombus within the ASA has occasionally been visualized by TEE.^{8,9} As mentioned above, ASA is often associated with PFO and mitral valve prolapsed, but in the present case it was accompanied with severe MS. So the history of CVA in our patient may be related to AF cardiac rhythm and underlying MS and not necessarily to the septal aneurysm. In conclusion, the ASA is not a rare abnormality and we should keep it in mind in every patient with an embolic event with unknown origin. The surgical indication of ASA depends on the concomitant abnormality or pathology.

References

1. Silver MD, Dorsey JS. Aneurysms of the septum primum in adults. *Arch Pathol Lab Med* 1978; 102: 62-65.
2. Gondi B, Nanda NC. Two-dimensional echocardiographic features of atrial septal neurysms. *Circulation* 1981; 63: 452-453.
3. Hauser AM, Timmis GC, Stewart JR, Ramos RG, Gangadharan V, Westveer DC, Gordon S. Aneurysm of the atrial septum as diagnosed by echocardiography: analysis of 11 patients. *Am J Cardiol* 1984; 53: 1401-1402.
4. Hanley PC, Tajik AJ, Hynes JK, Edwards WD, Reeder GS, Hagler DJ, Seward JB. Diagnosis and classification of atrial septal aneurysm by two-dimensional echocardiography: report of 80 consecutive cases. *J Am Coll Cardiol* 1985; 6: 1370-1382.
5. Wolf WJ, Casta A, Sapire DW. Atrial septal aneurysms in infants and children. *Am Heart J* 1987; 113: 1149-1153.
6. Brand A, Keren A, Branski D, Abrahamov A, Stern S. Natural course of atrial septal aneurysm in children and the potential for spontaneous closure of associated septal defects. *Am J Cardiol* 1989; 64: 996-1001.
7. Roberts WC. Aneurysm (redundancy) of the atrial septum (fossa ovale membrane) and prolapse (redundancy) of the mitral valve. *Am J Cardiol* 1984; 54: 1153-1154.
8. Iliceto S, Papa A, Sorino M, Rizzon P. Combined atrial septal aneurysm and mitral valve prolapse: detection by two-dimensional echocardiography. *Am J Cardiol* 1984; 54: 1151-1154.
9. Belkin RN, Waugh RA, Kisslo J. Interatrial shunting in atrial septal aneurysm. *Am J Cardiol* 1986; 57: 310-312.
10. Belkin RN, Kisslo J. Atrial septal aneurysm: recognition and clinical relevance. *Am Heart J* 1990; 120 (4): 948–57.
11. Shenoy MM, Vijaykumar PM, Friedman SA, Greif E. Atrial septal aneurysm associated with systemic embolism and interatrial right-to-left shunt. *Arch Intern Med* 1987; 147: 605–6.
12. Limburg M, Wijdicks EFM, Li H. Ischemic stroke after surgical procedures: clinical features, neuroimaging, and risk factors. *Neurology* 1998; 50: 895–901.